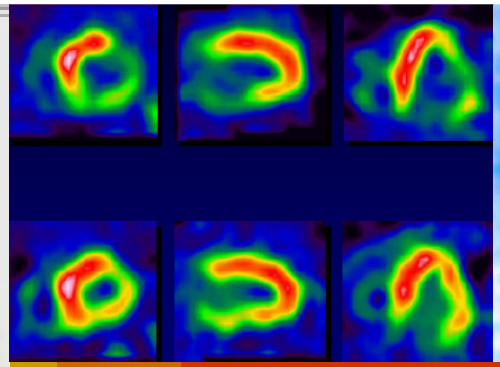

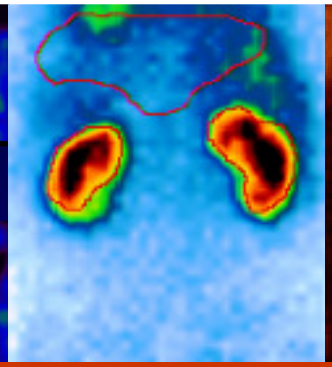

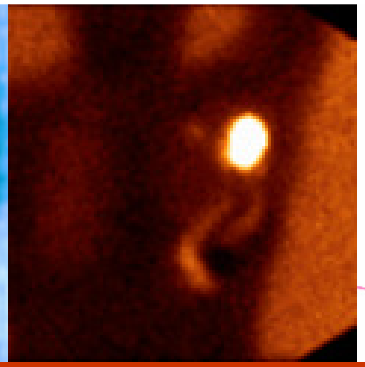

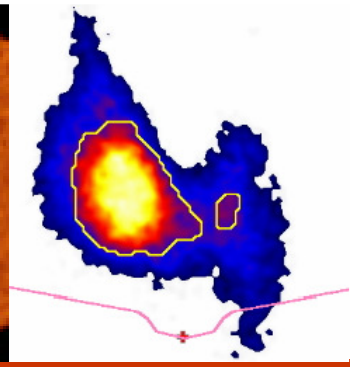

Nuklearmedizin & Radiologie

SPECT-CT

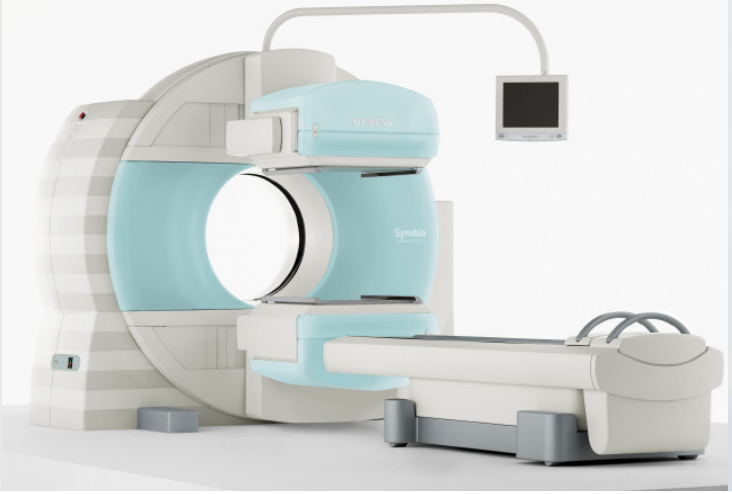

PET/CT

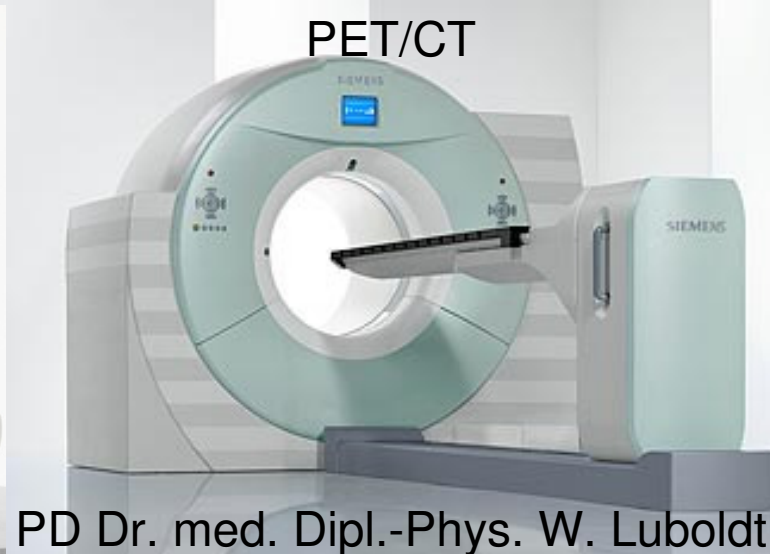

PD Dr. med. Dipl.-Phys. W. Luboldt

Tracer + Radionuklid =>Diagnostik*(/Therapie)

- Skelett:	MDP - Chemisorption von Phosphonat an Knochenoberfl.
- Myokard-Perfusion:	MIBI - Aufn. in Myokard-Zelle
- Nieren-Funktion:	MAG3 - Tubuläre Sekretion
- Schilddrüse:	Pertechnetat Na-Jodid Symporter
- Lymphabfluß:	MAA - Partikeltransport
- Stoffwechsel:	z.B. Glucose-Metabolismus
- Rezeptoren:	Rezeptor-Liganden-Interaktion
- etc.	

* die Konzentrationen liegen unter der „Allergiegrenze“

Gliederung

Gamma-Kamera: γ (Photonen) (Technetium)

PET: β^+ (Positronen) (511 keV, 180°-Koinzidenz)

Therapie: β^- (Elektronen) (mm-Reichweite)

γ-Diagnostik

Ganzkörper-Knochen-Szintigraphie

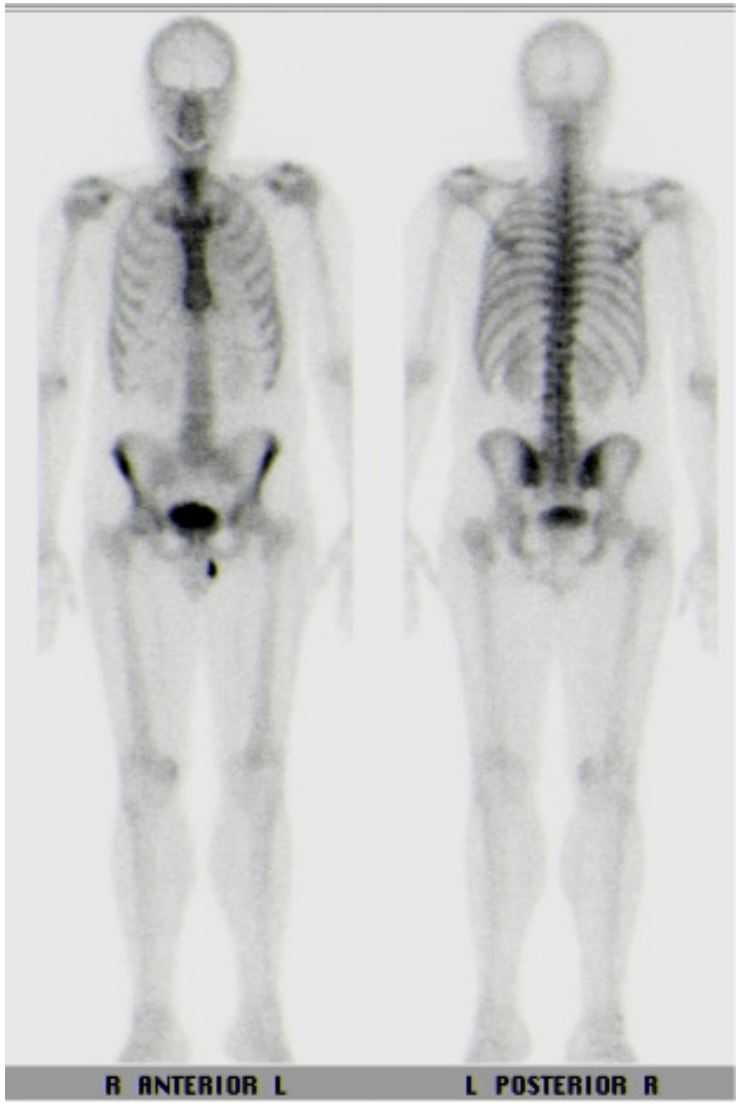

γ

Methylendiphosponat $(MDP)_2$

+

^{99m}Tc ($T_{1/2}$=6 h)

Aktivität (5-10 MBq/kg BW):
- 500 MBq (Synovialitis?)
- 750 MBq (KnochenMets?)

ca. 500-1000 MBq

+

Weichteilphase
(Hyperämie)
10 min. p.i.

Spätphase
(Mineralisation)
2 Std p.i.

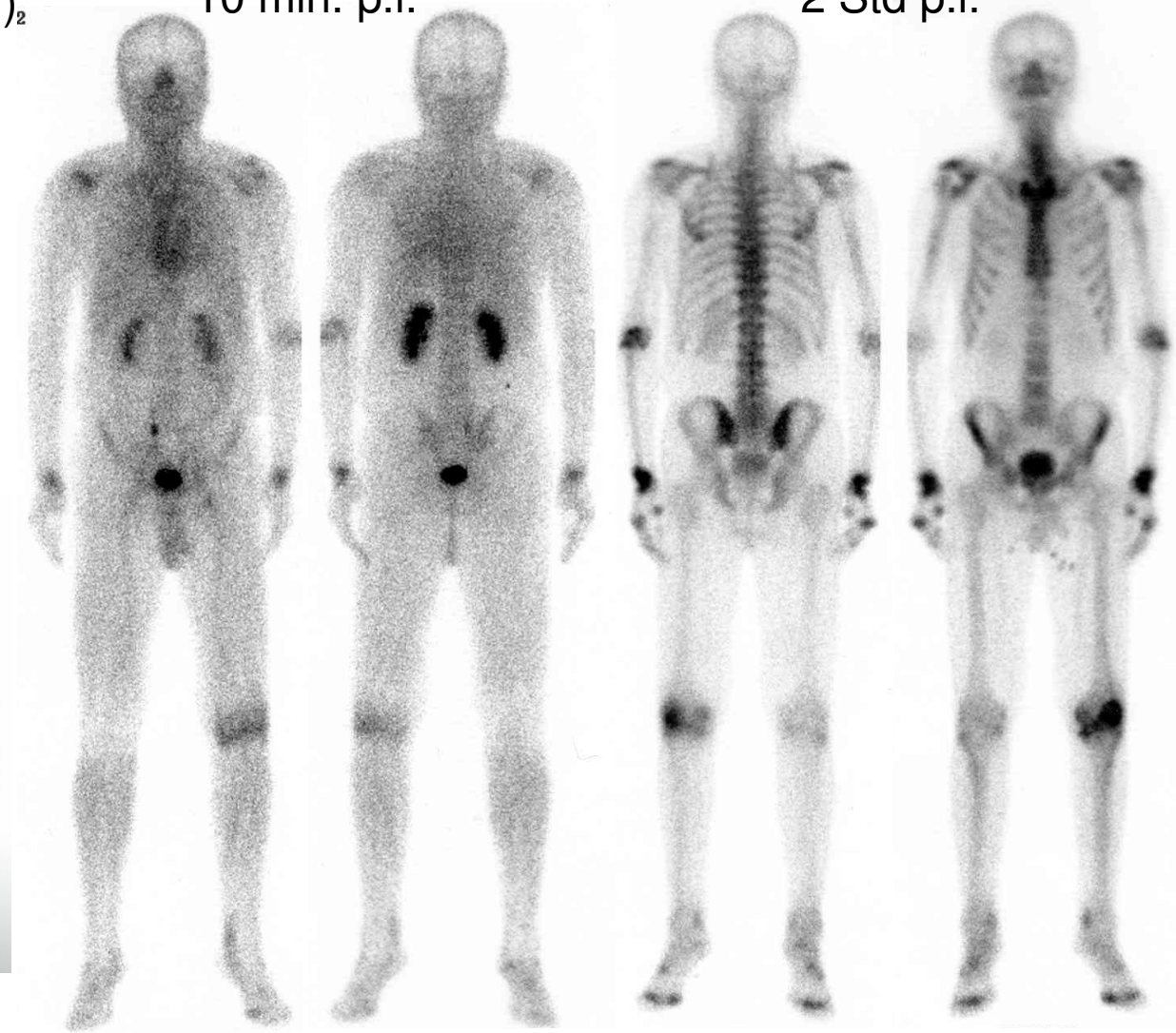

anterior posterior anterior posterior

γ

Primärtumor	Häufigkeit (%)	
Mammakarzinom	50 - 85	eher osteolystisch
Prostatakarzinom	50 - 75	osteoblastisch!
Bronchialkarzinom	30 - 50	osteolystisch
Nierenzellkarzinom	30 - 50	osteolystisch
Schilddrüsenkarzinom	30	
Pankreaskarzinom	5 - 10	
kolorektale Karzinome	5 - 10	
Magenkarzinom	5 - 10	
Leberzellkarzinom	8	
Ovarialkarzinom	2 - 6	

PSA > 15 ng/ml

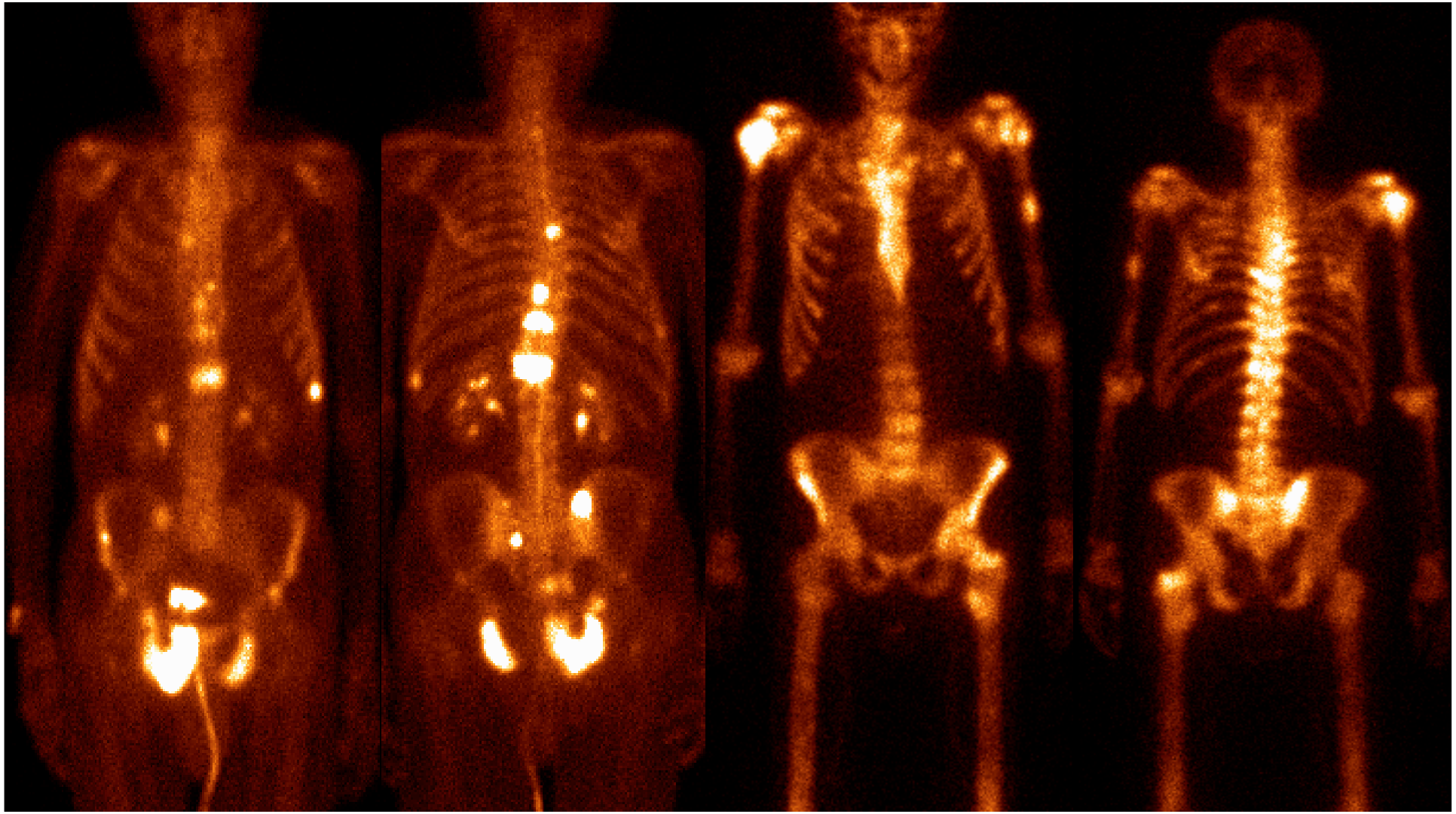

Hyper-/Superscan (keine Nieren)

γ

ProstataCA

MammaCA

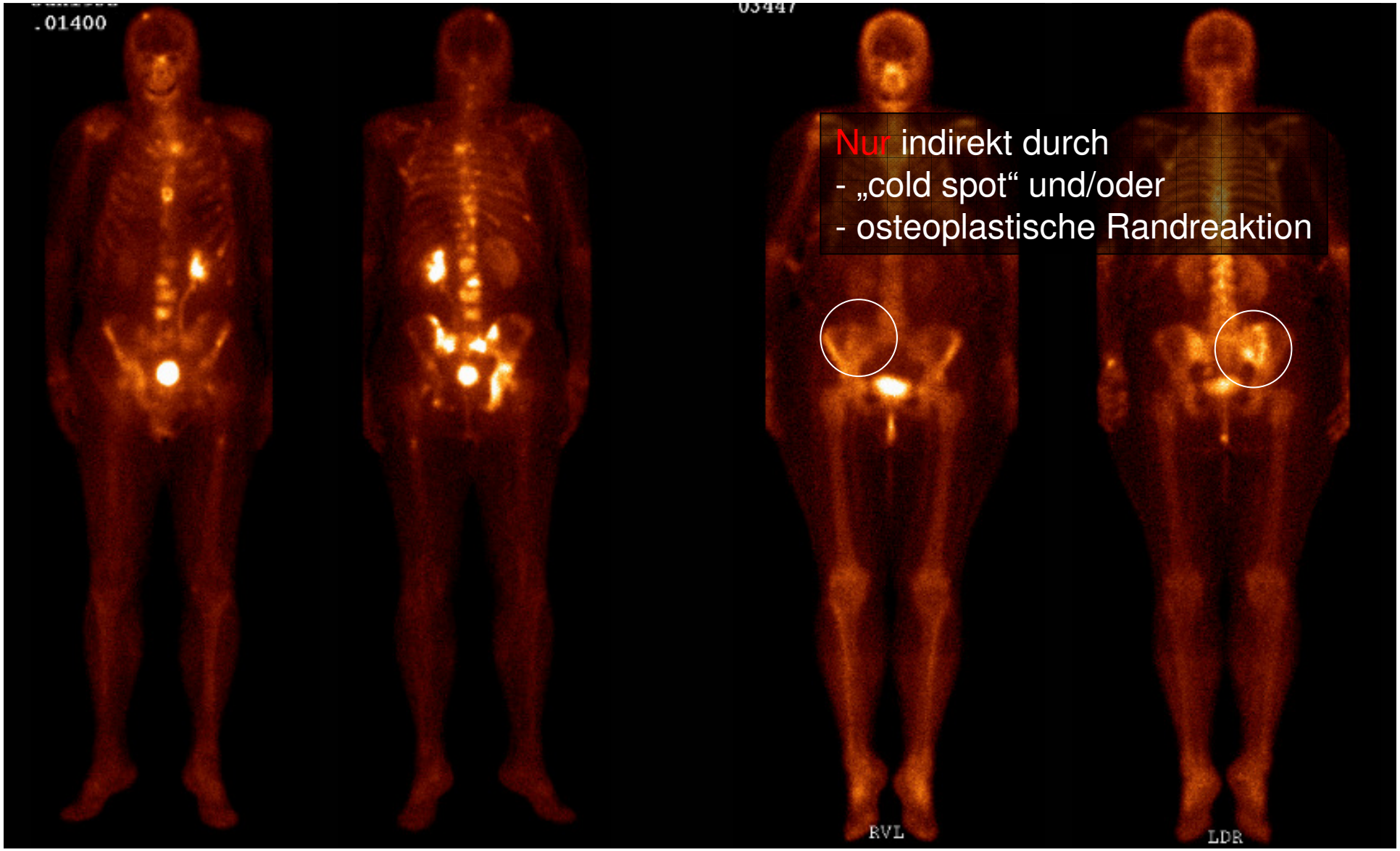

Nur indirekt durch
- „cold spot“ und/oder
- osteoplastische Randreaktion

osteoblastisch

osteolytisch

γ

Hyperämie (10 p.i) = itis

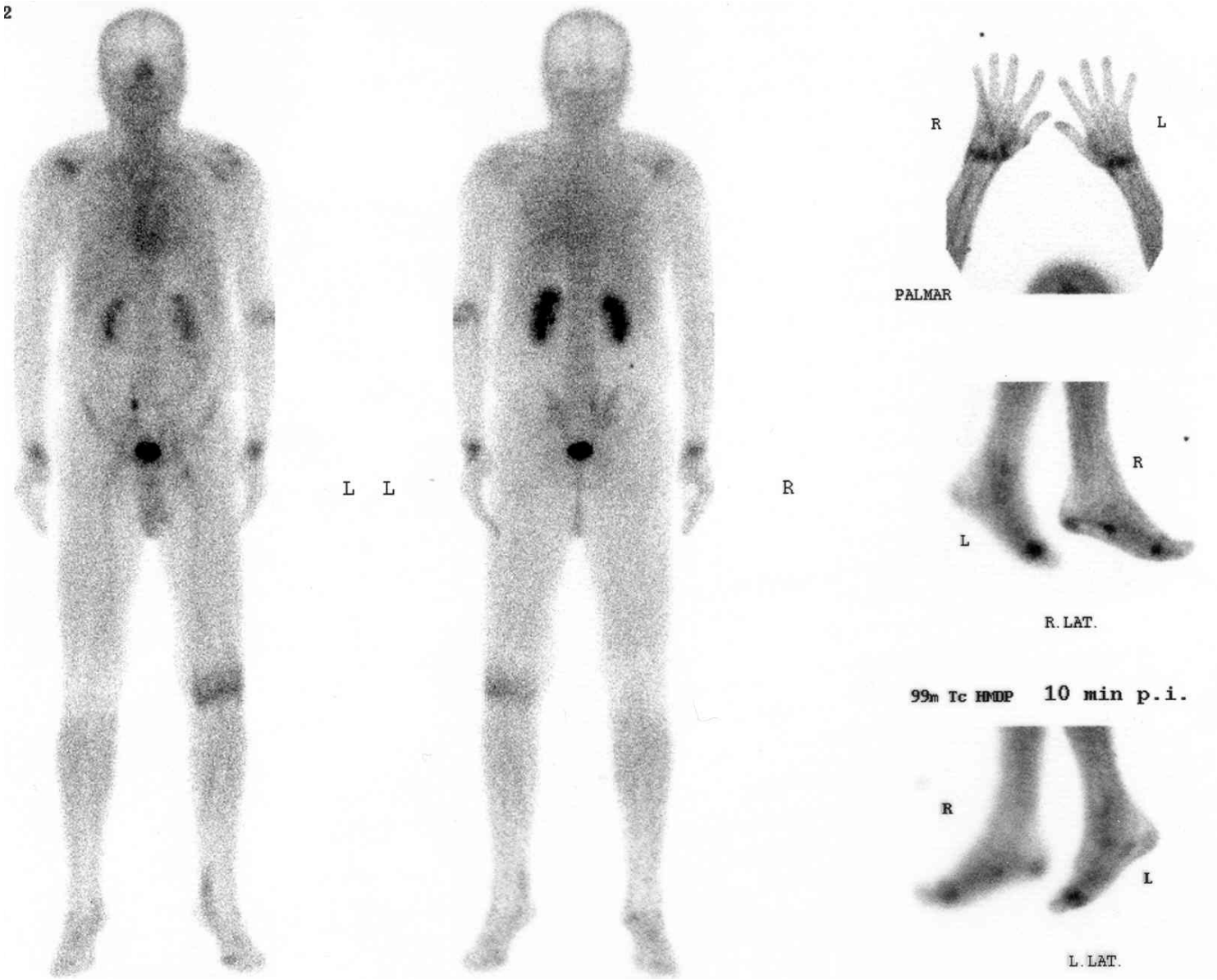

Synovialitis bei Knie-TEP

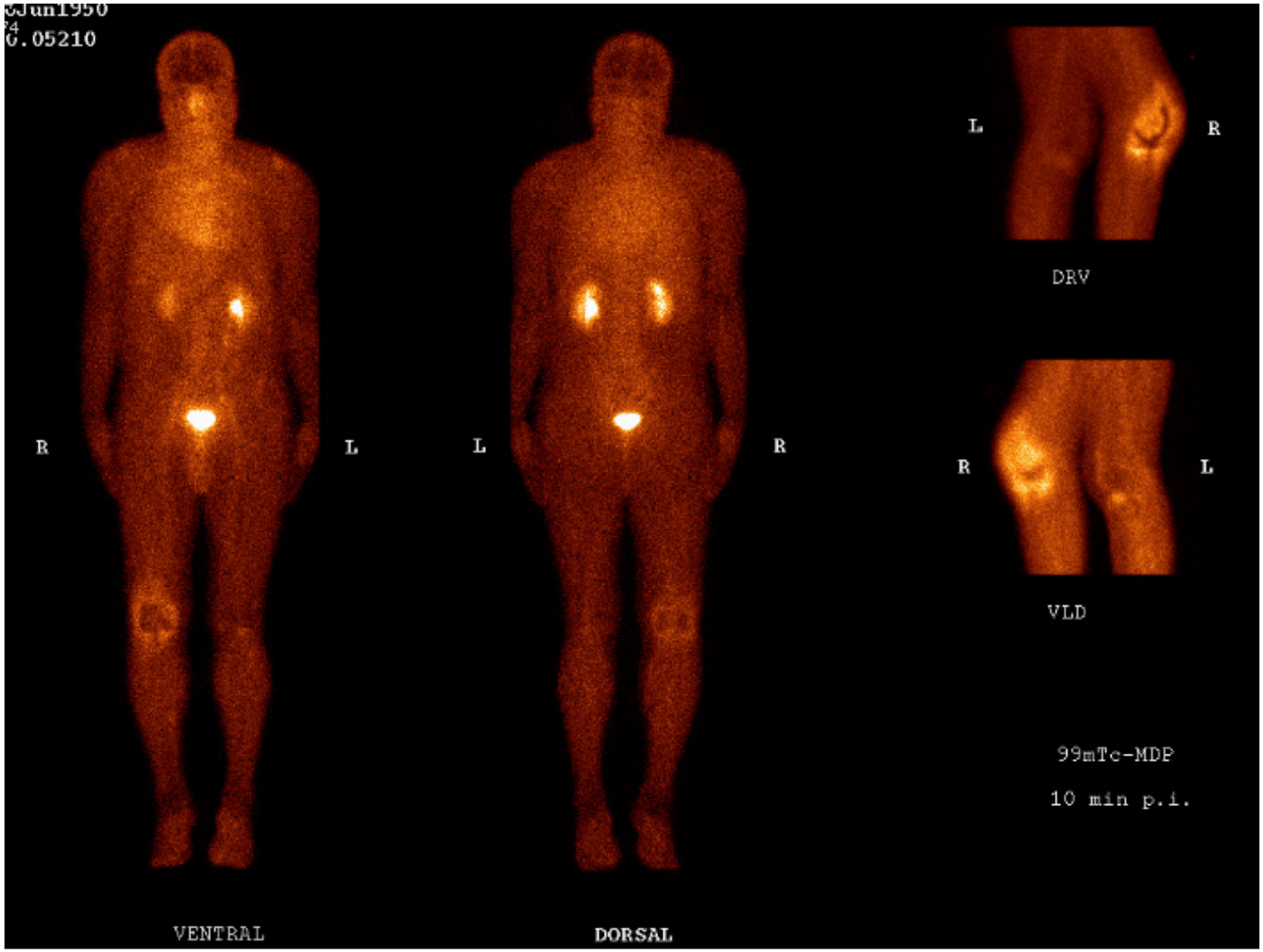

Myokard-Szintigraphie

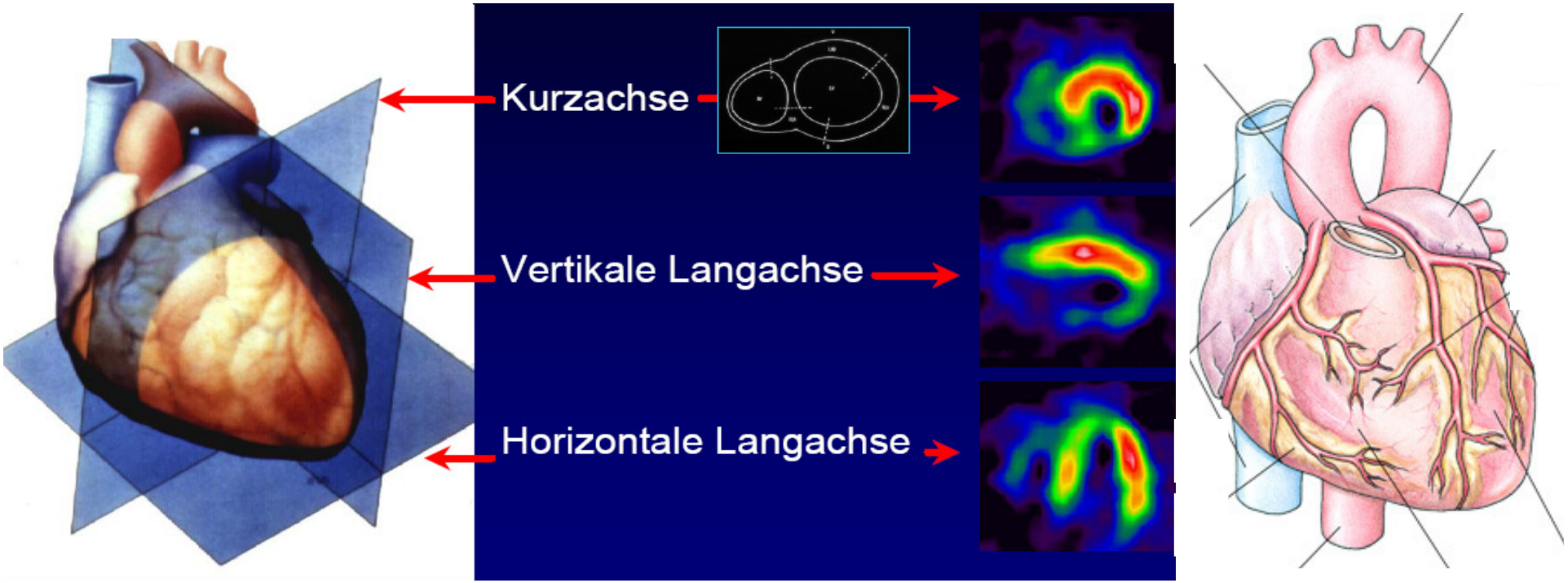

Ischämie-Kaskade

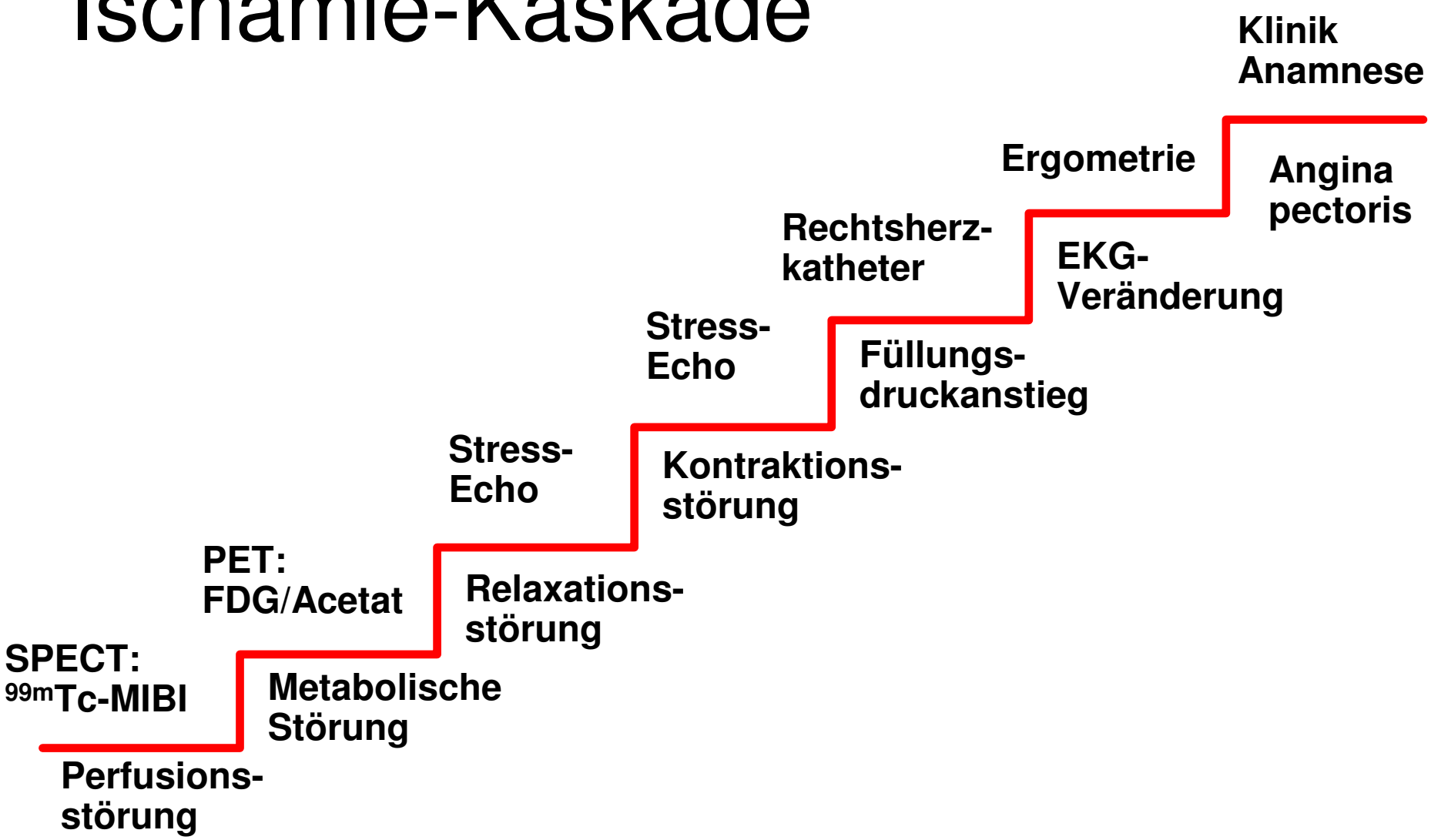

Steal-Phänomen

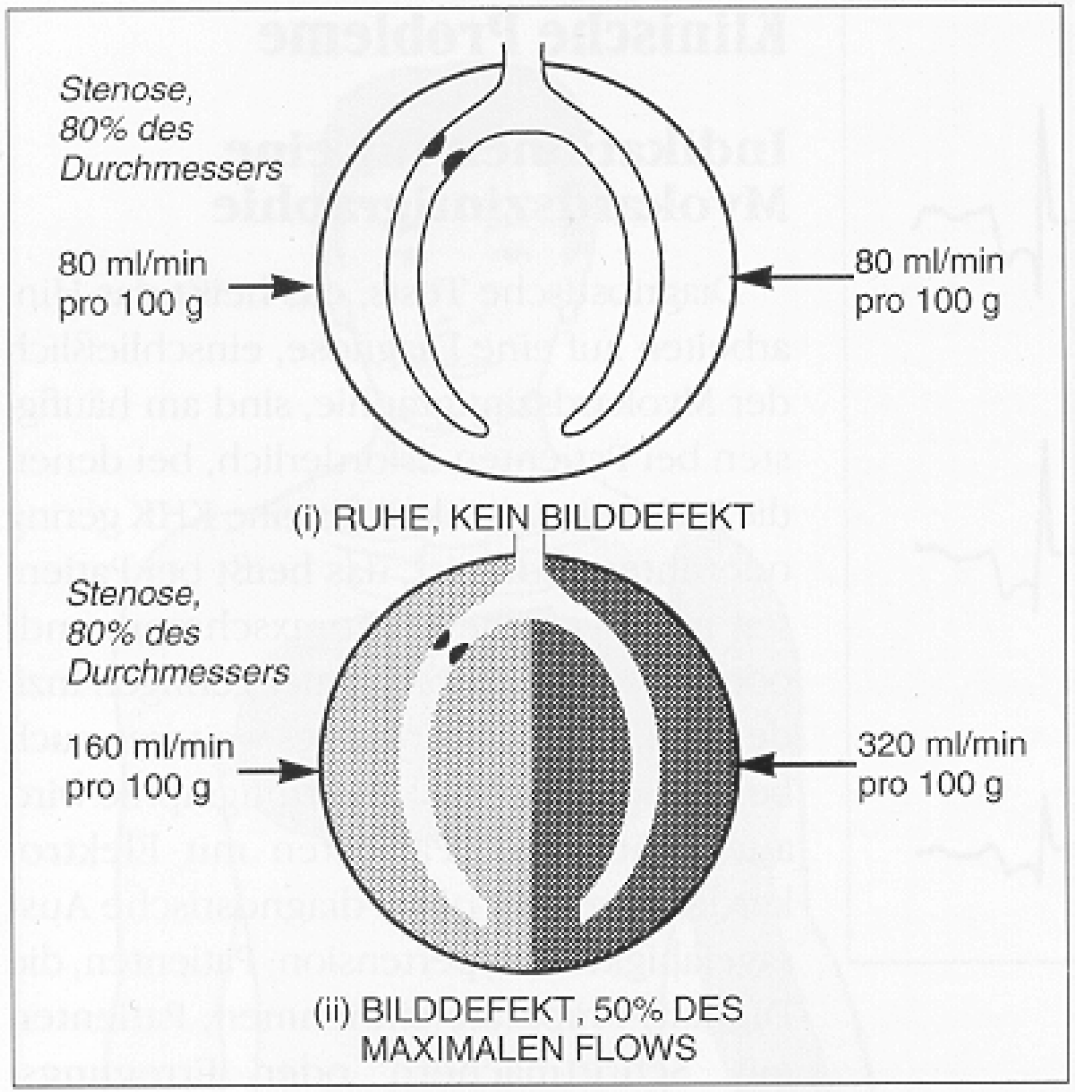

Normalbefund

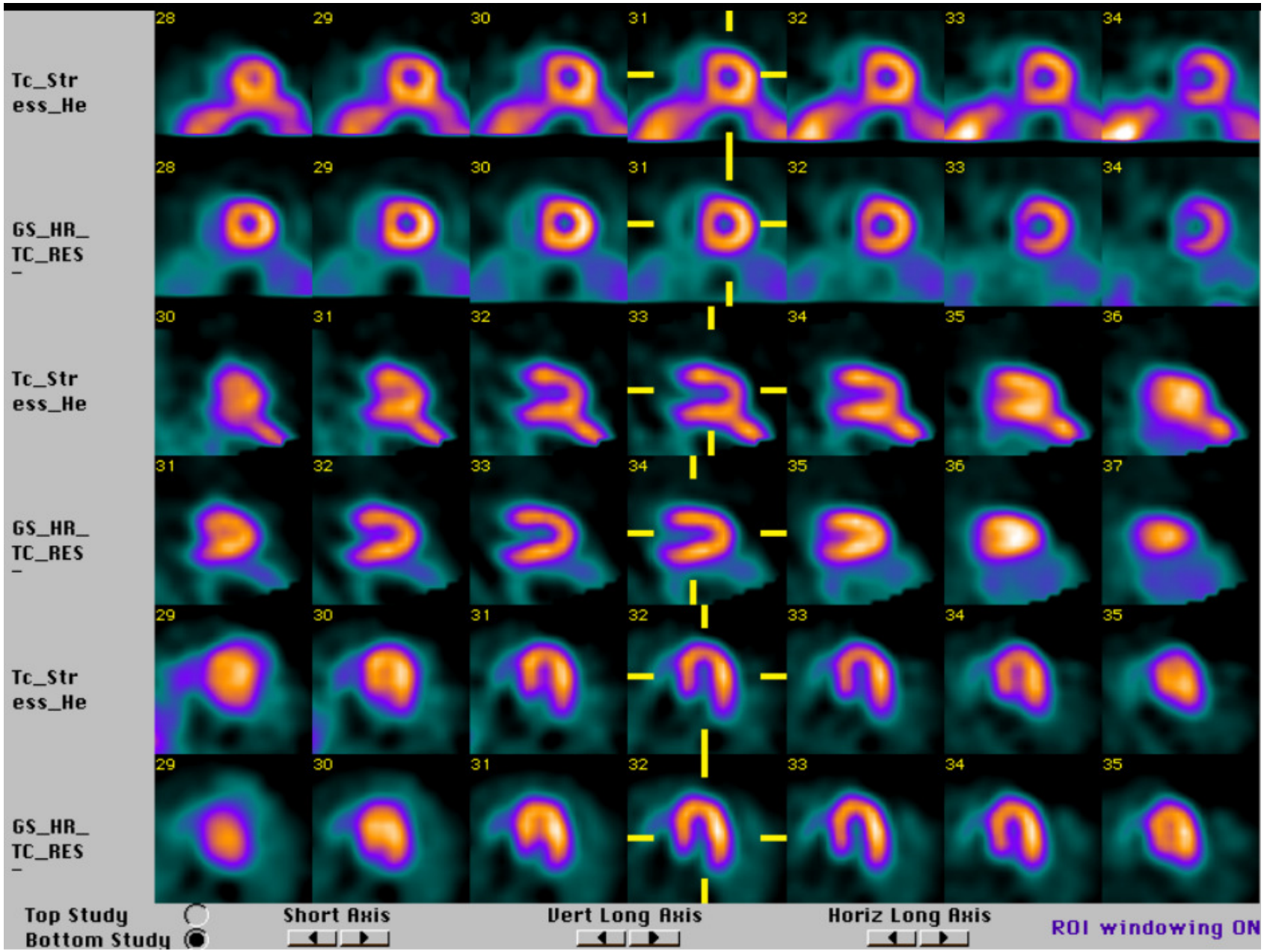

γ

Reversible, belastungsinduz. Ischämie

Stress

Ruhe

Stress

Ruhe

Stress

Ruhe

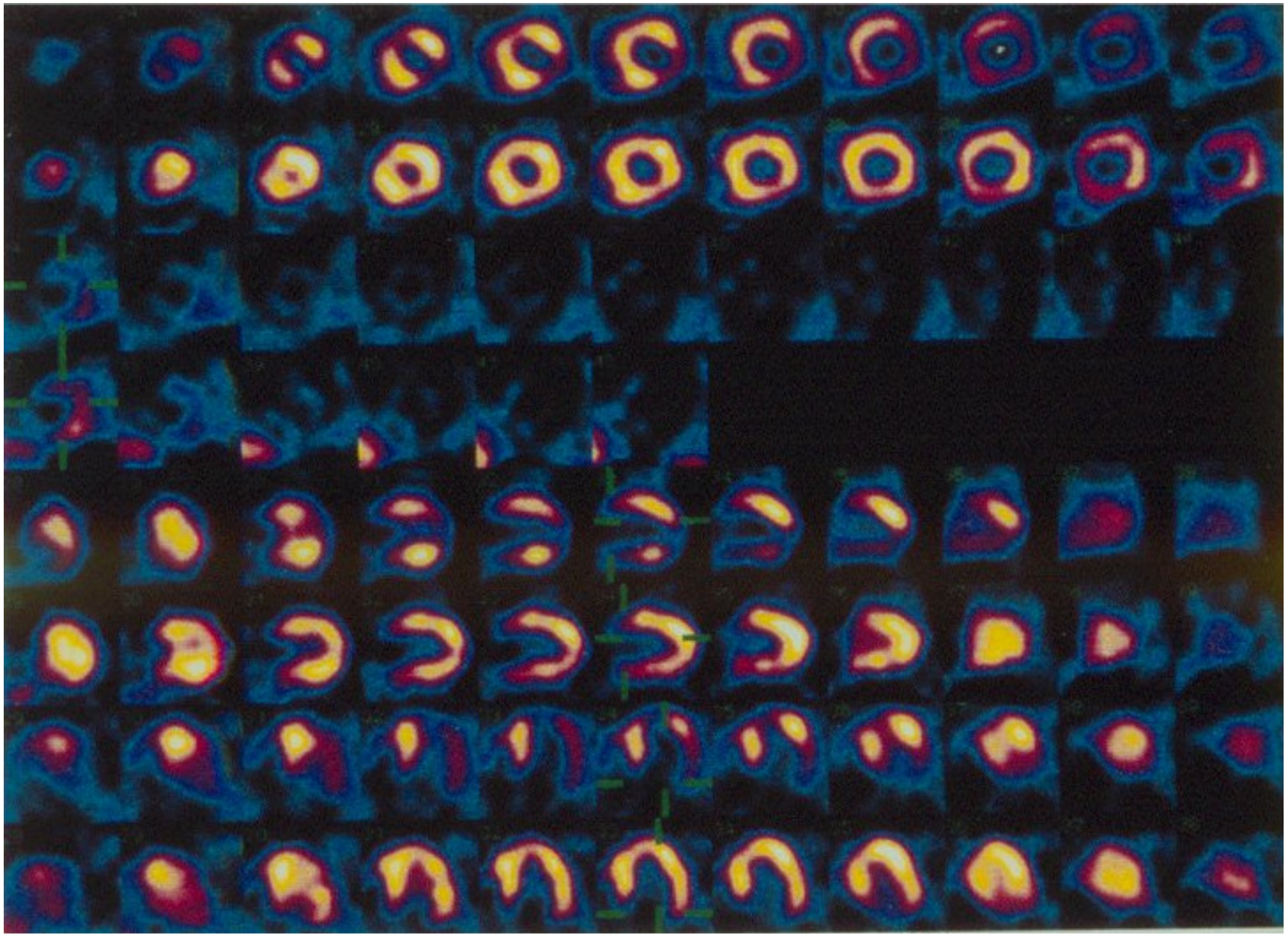

Reversible, belastungsinduz. Ischämie

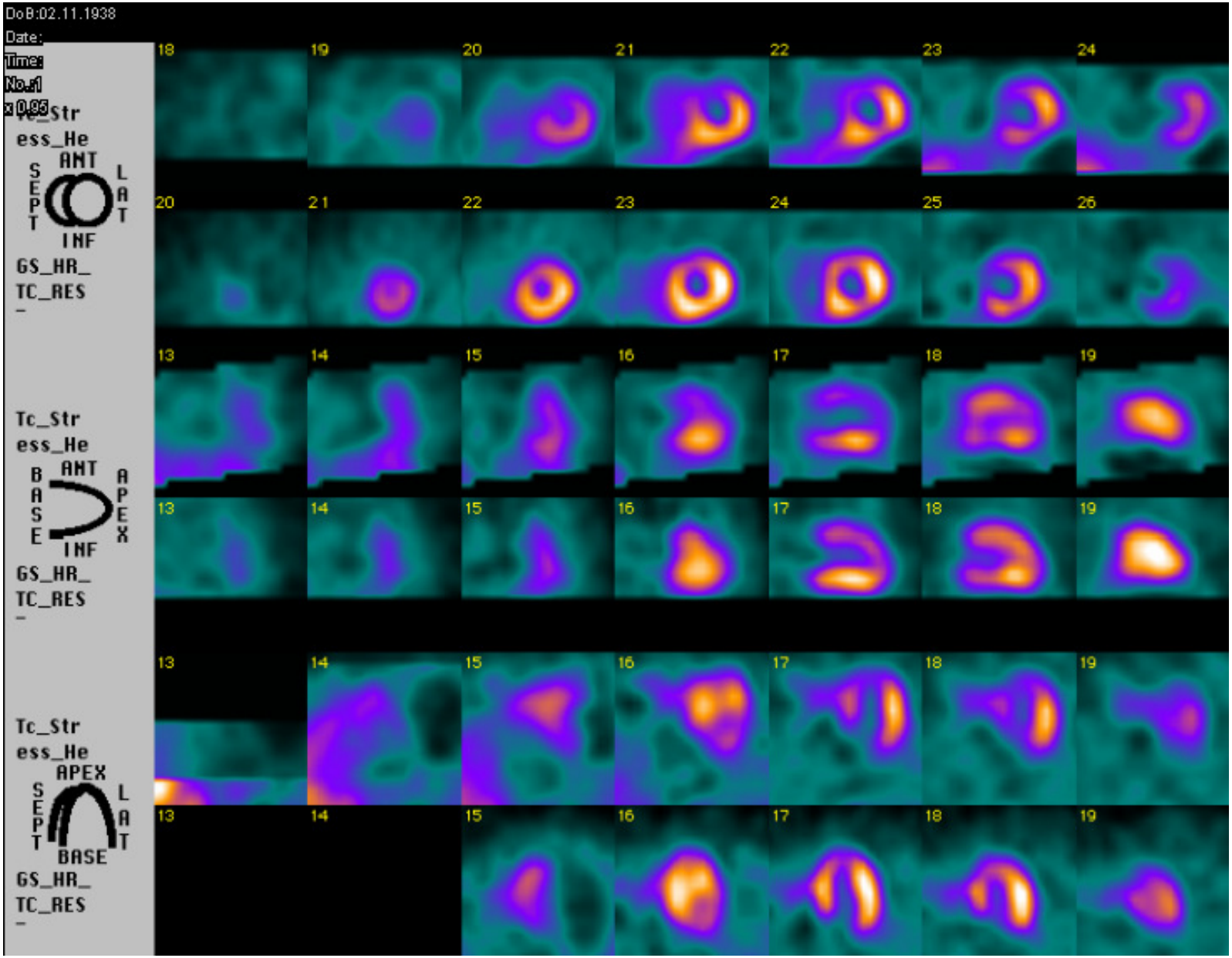

Myokardinfarkt

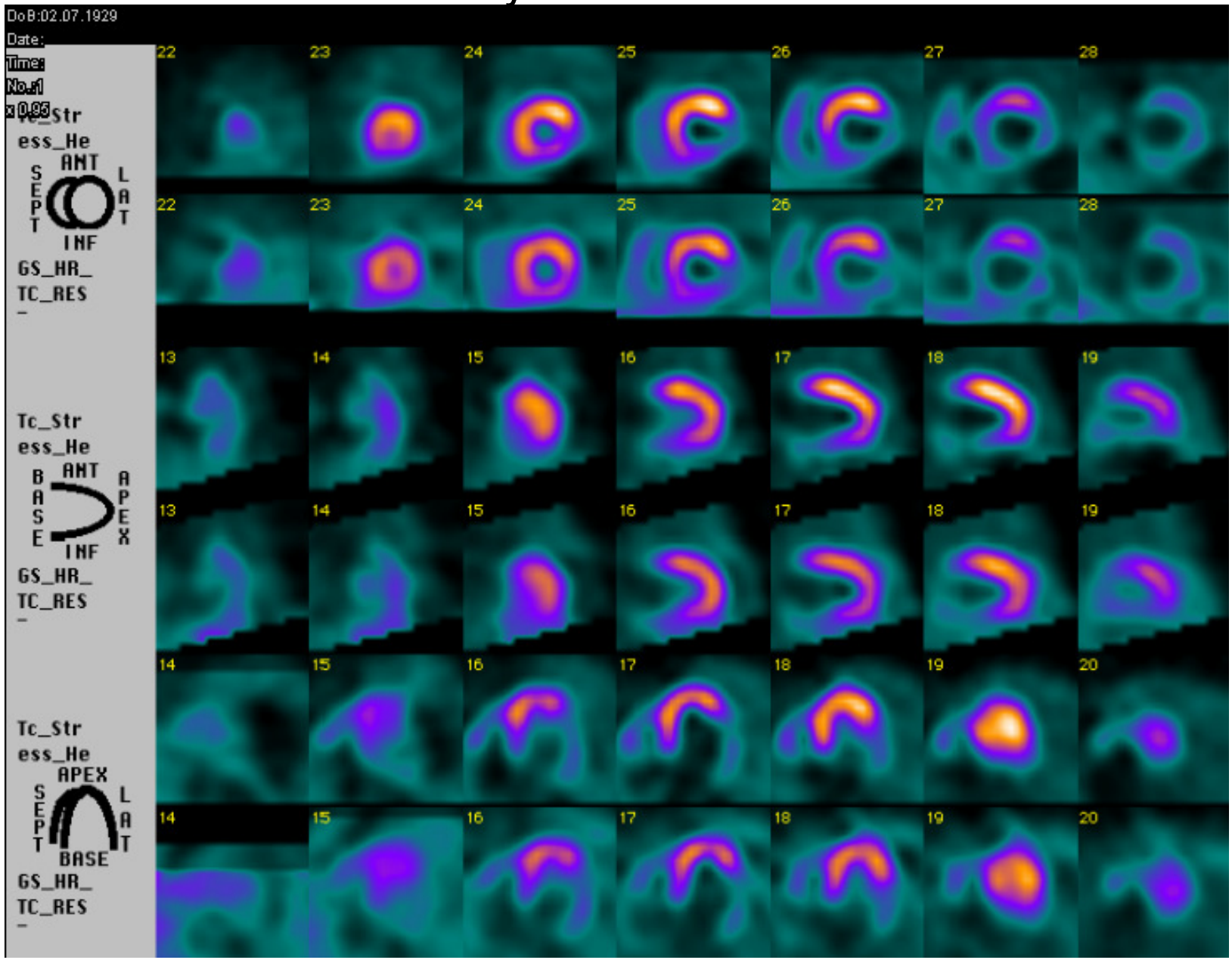

Myokardinfarkt

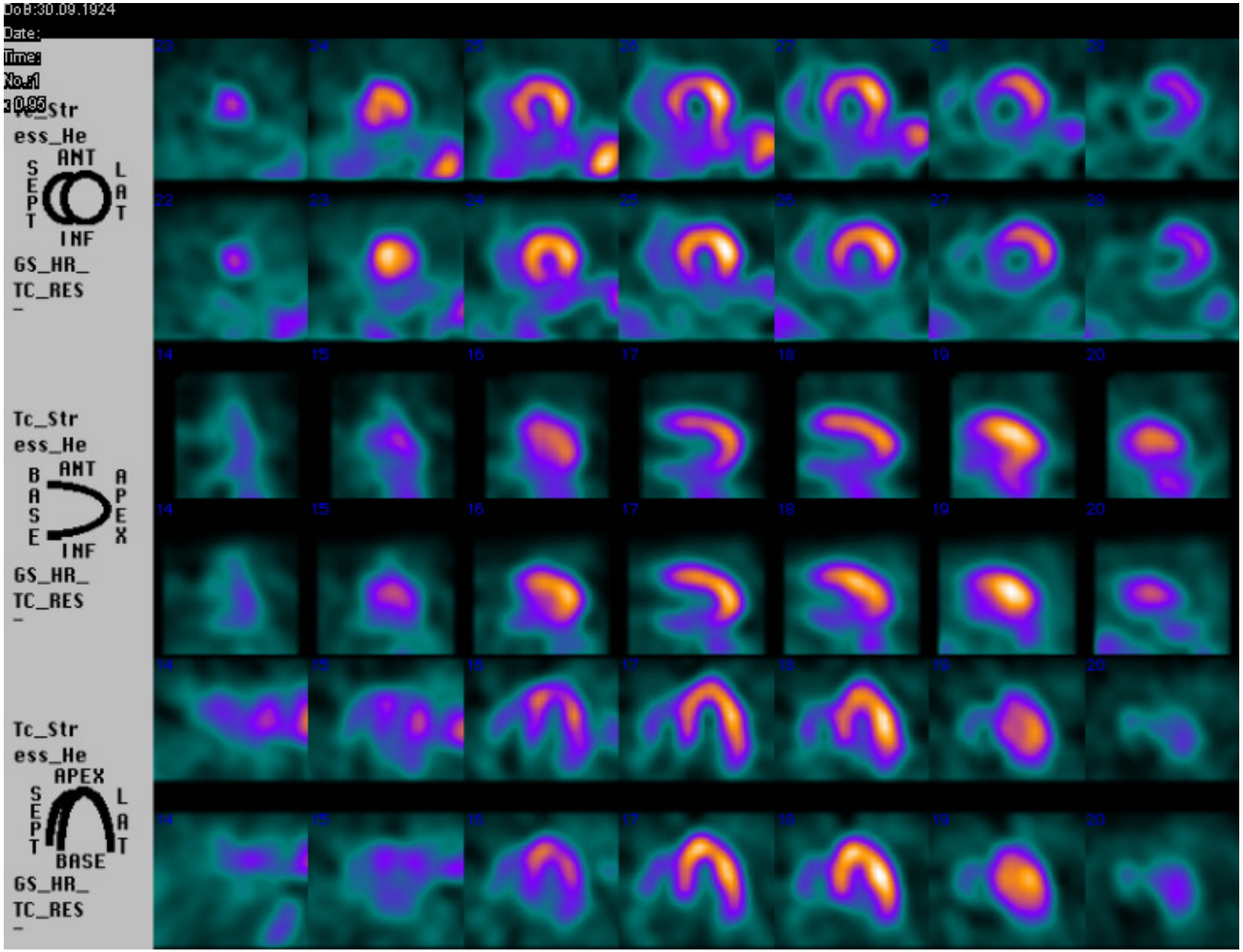

Nierenszinitgraphie

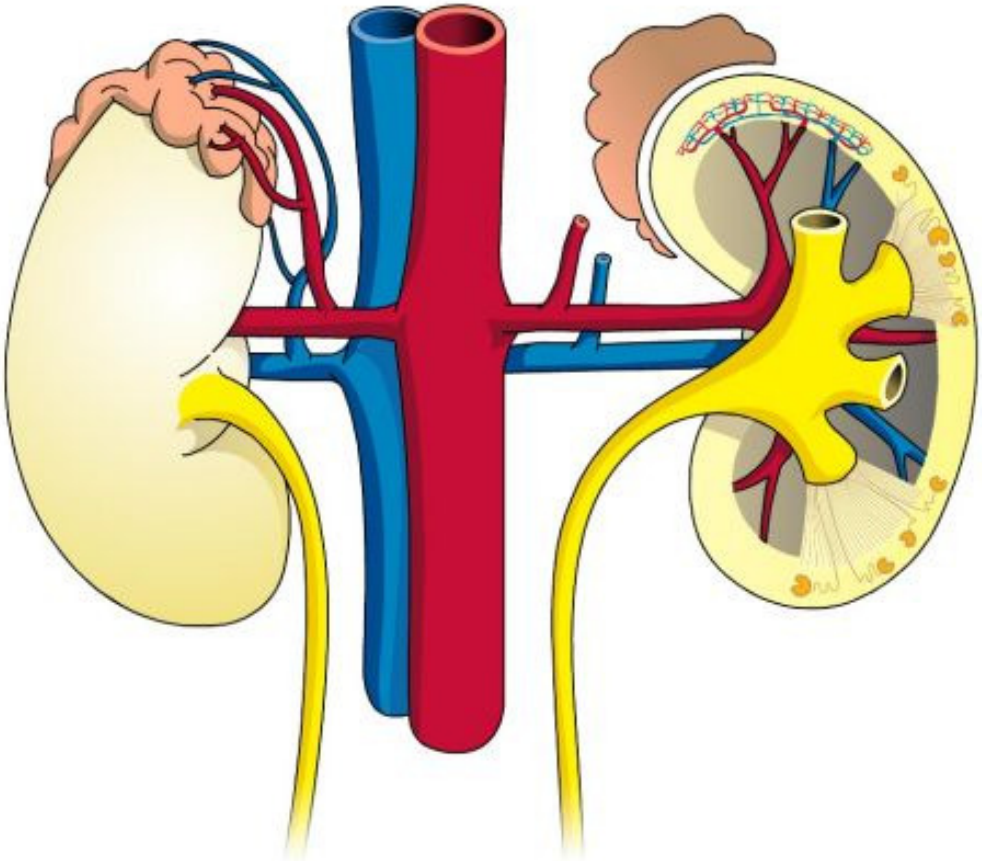

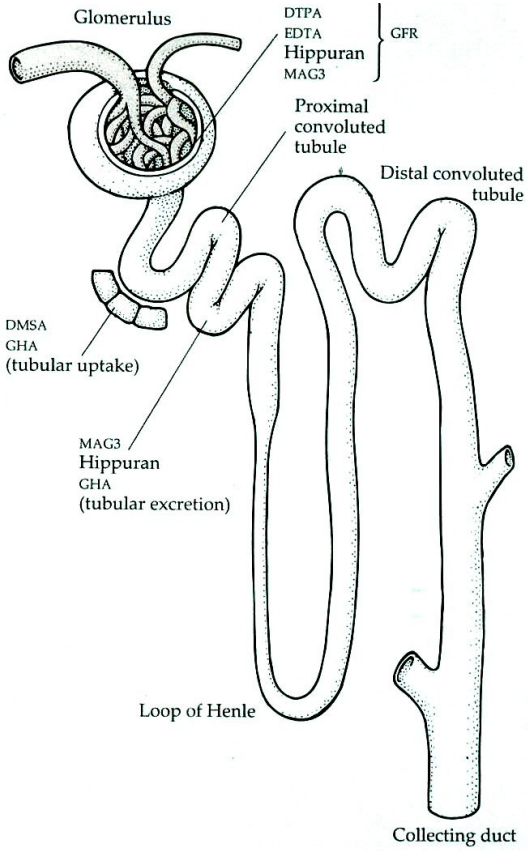

i.v. Applikation von ^{99m}Tc-MAG tubuläre Exkretion

Normalbefund

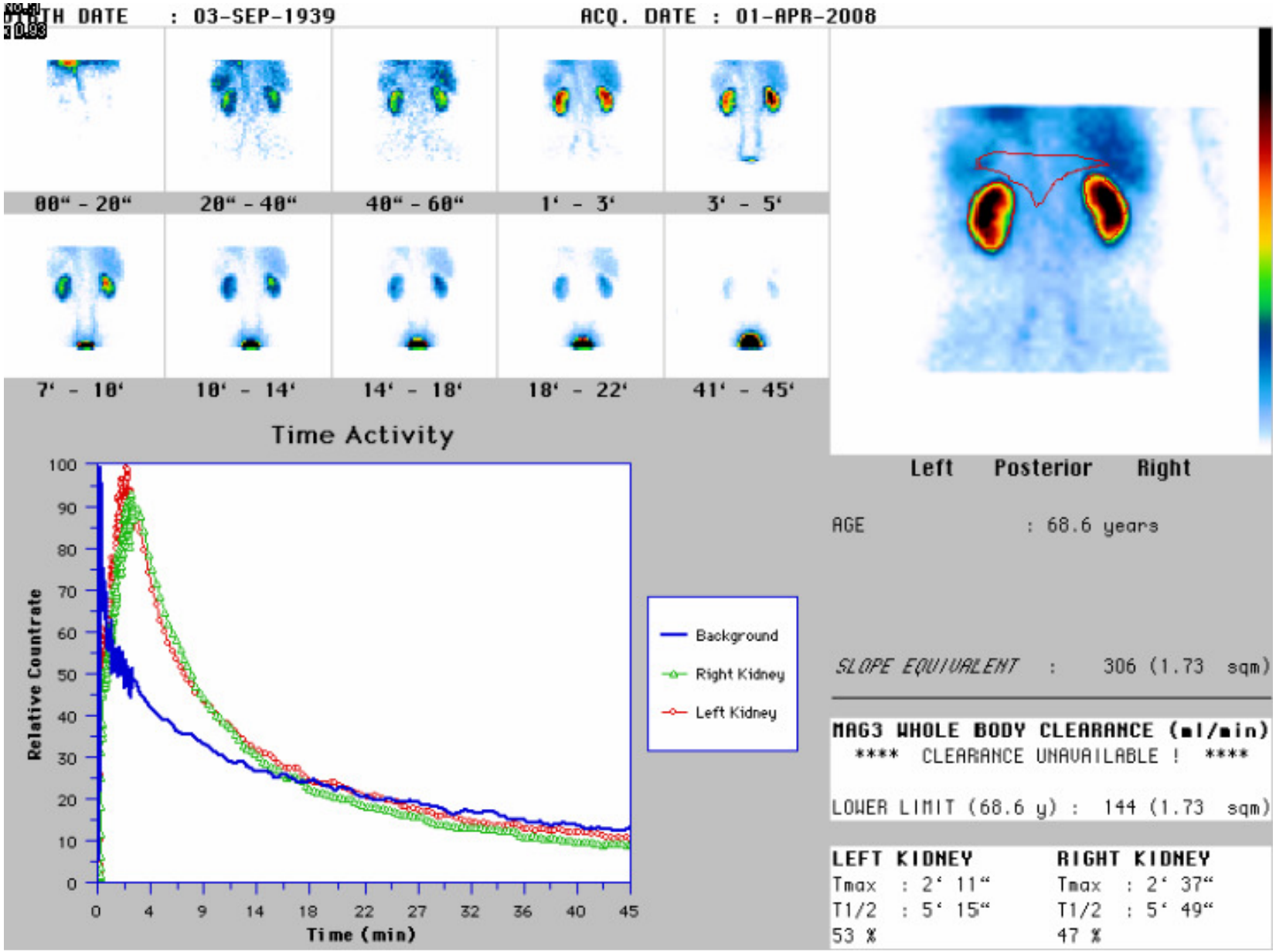

Obstruktion

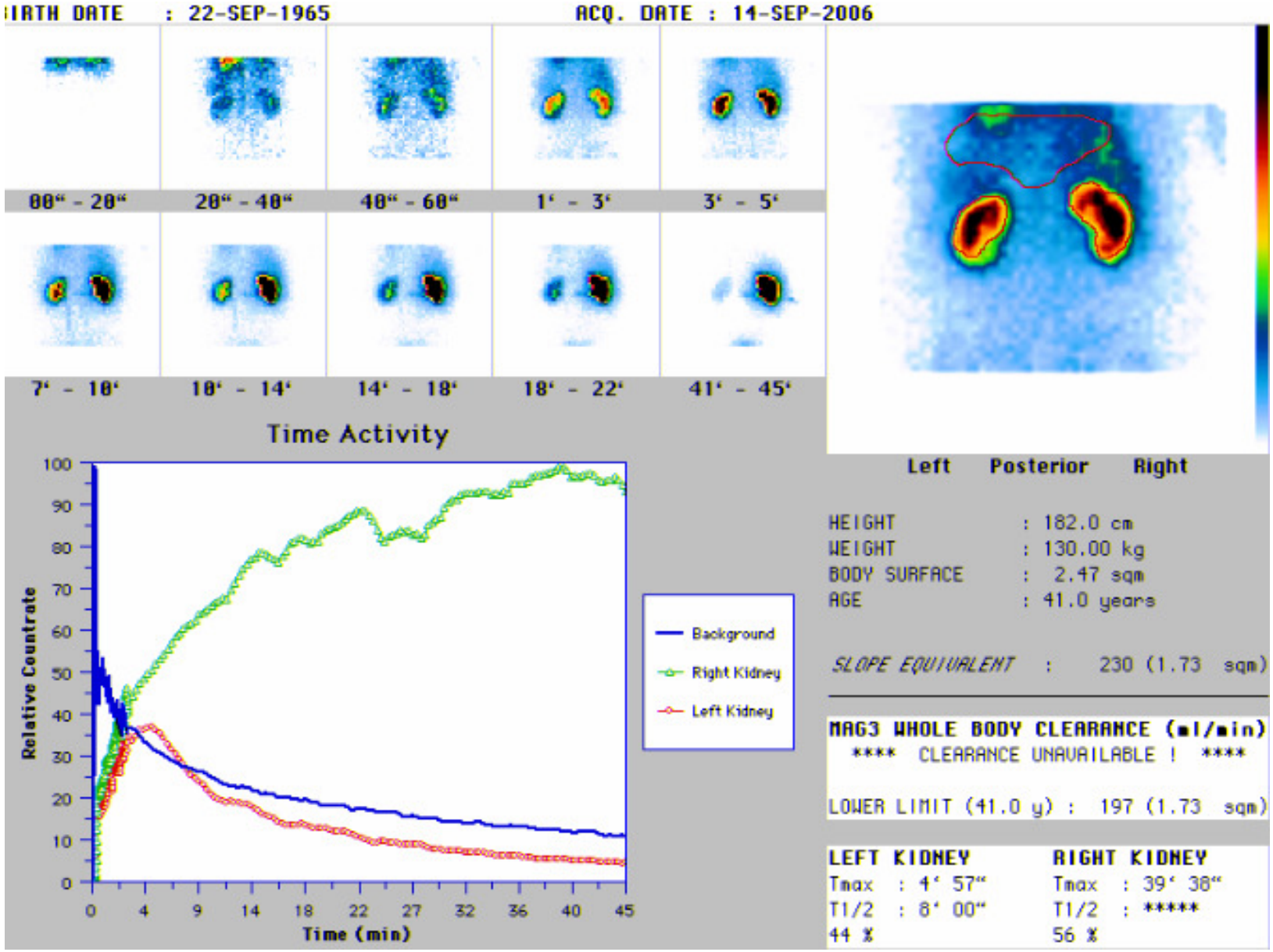

„Funktionelle Harntransportstörung“

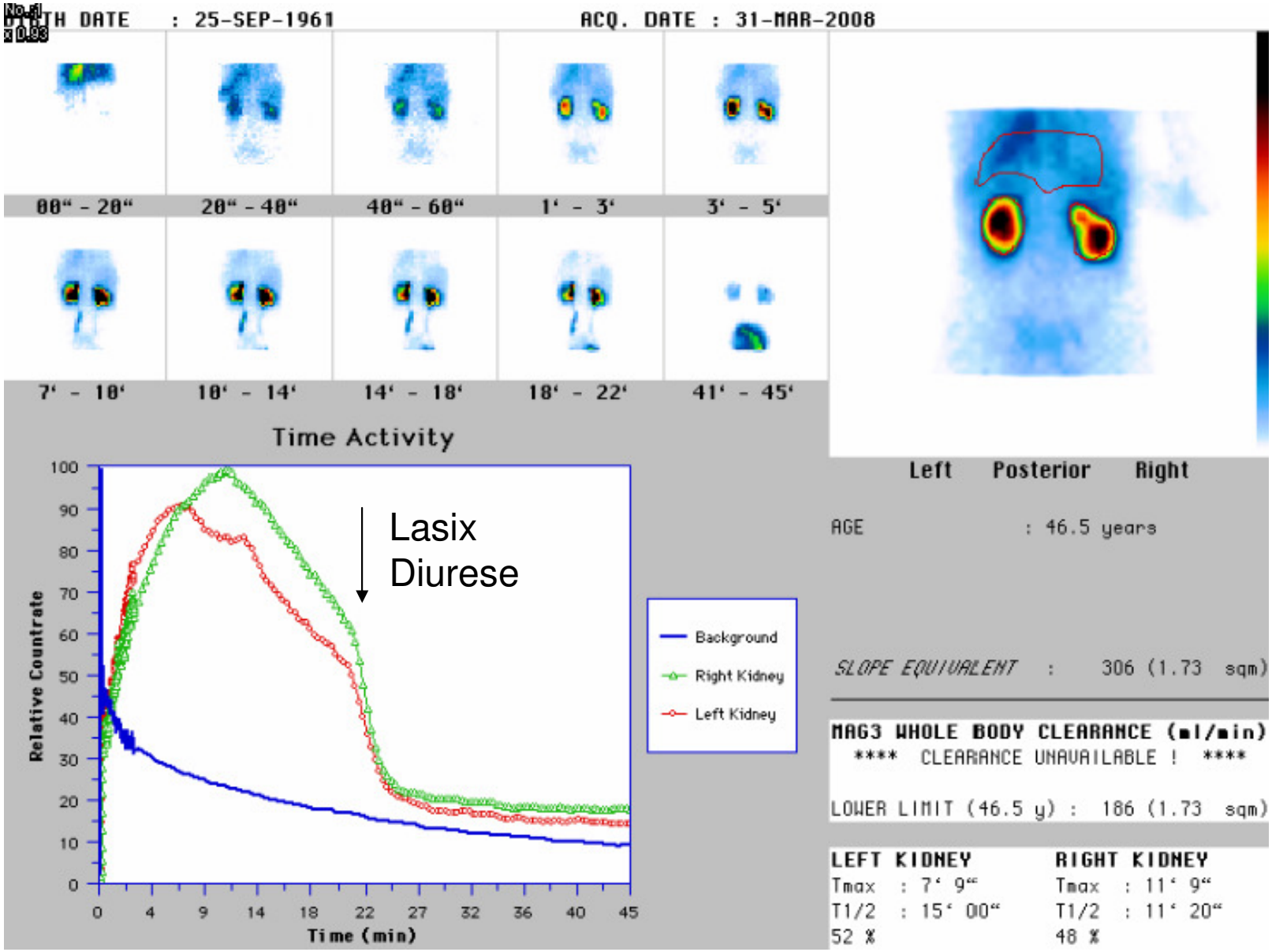

Lungenszinitgraphie

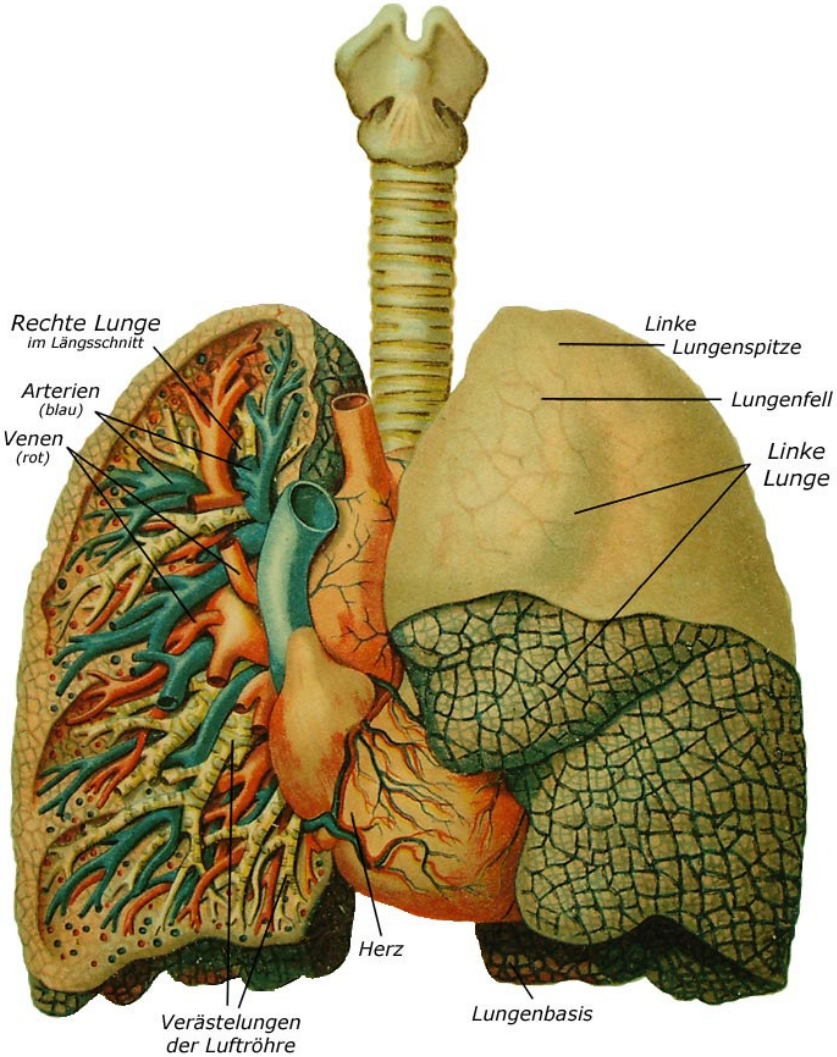

Lungenarterienembolie (LAE)

Ventilation

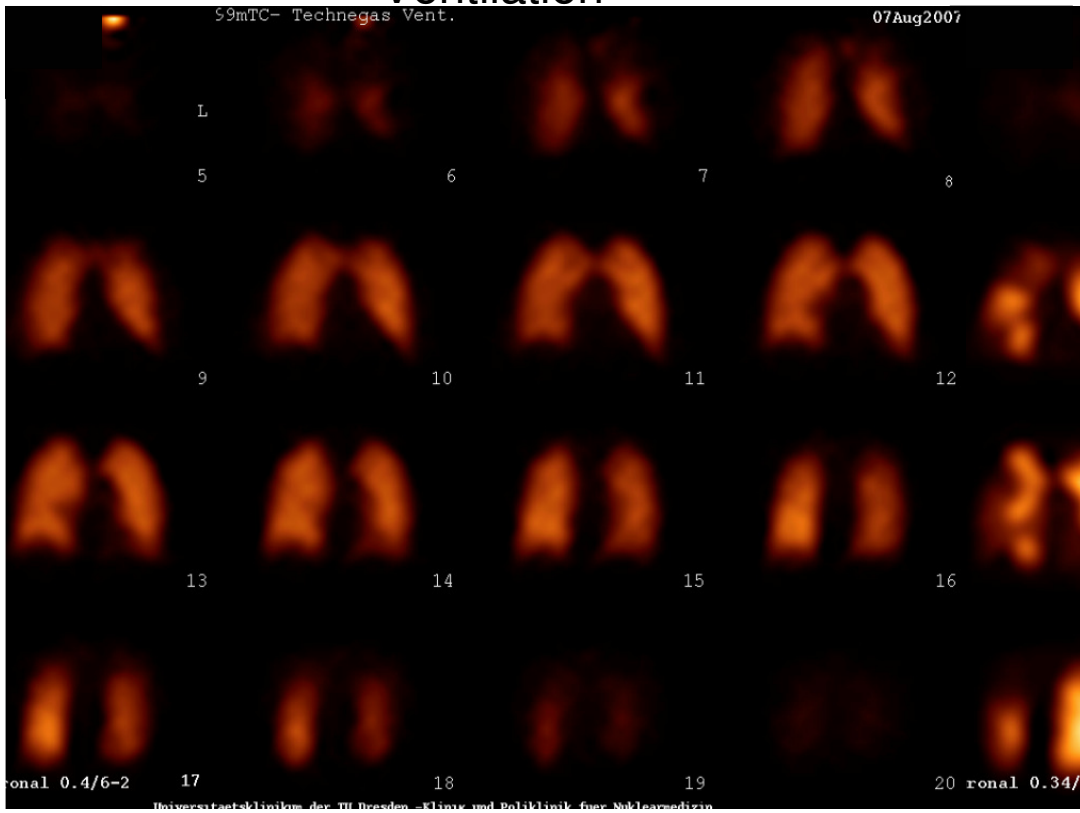

Perfusion

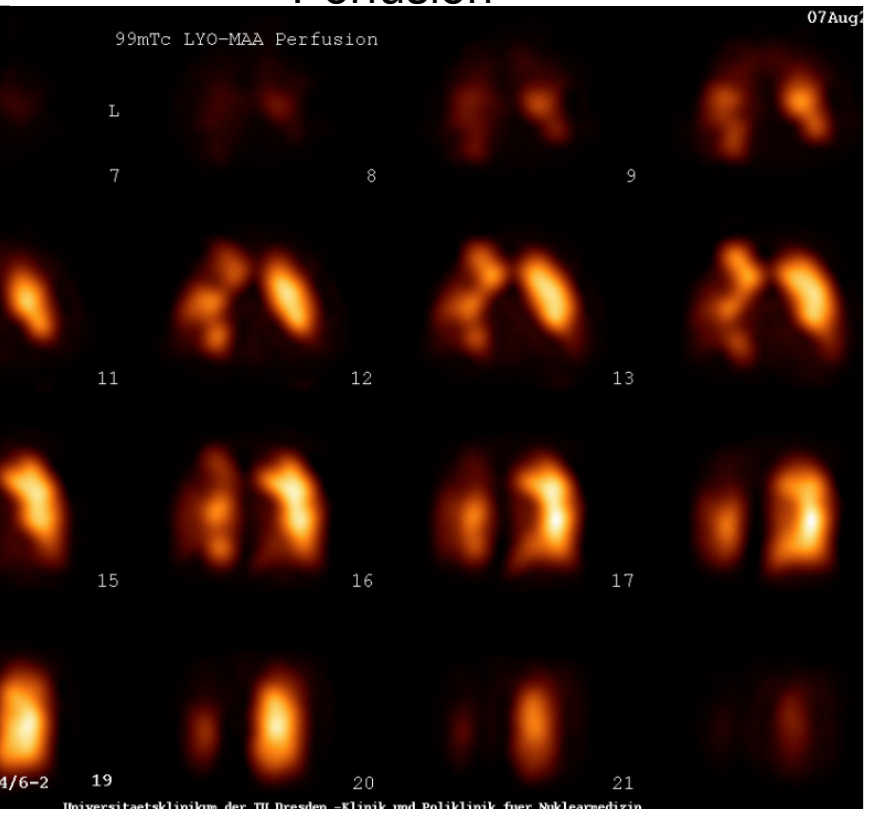

Inhalation von Tc-Gas

i.v. radioaktive Eiweißpartikeln =>
Mikroembolie in jeder 10.000sten Kapillare

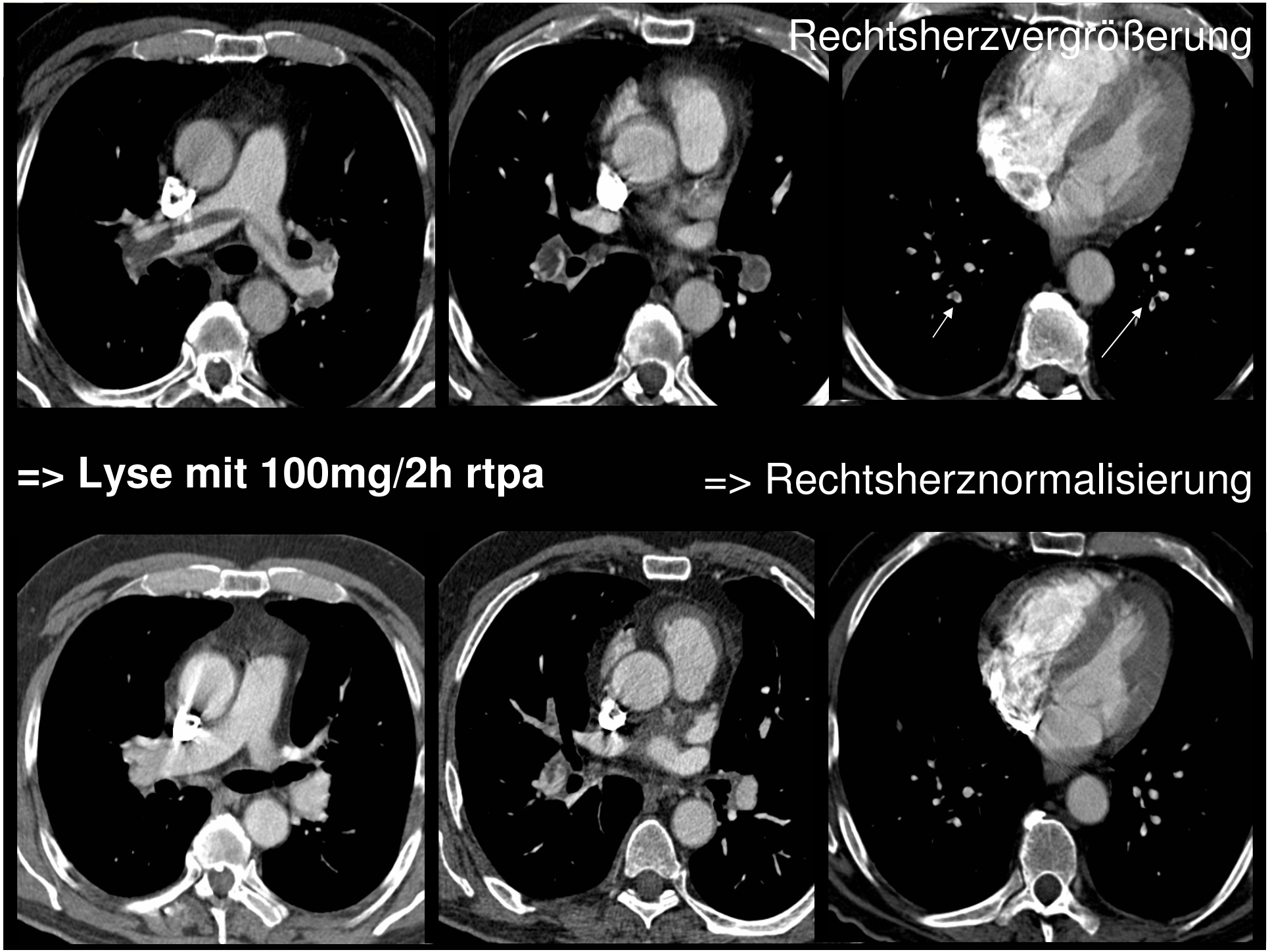
Rechtsherzvergrößerung
=> Lyse mit 100mg/2h rtpa
=> Rechtsherznormalisierung

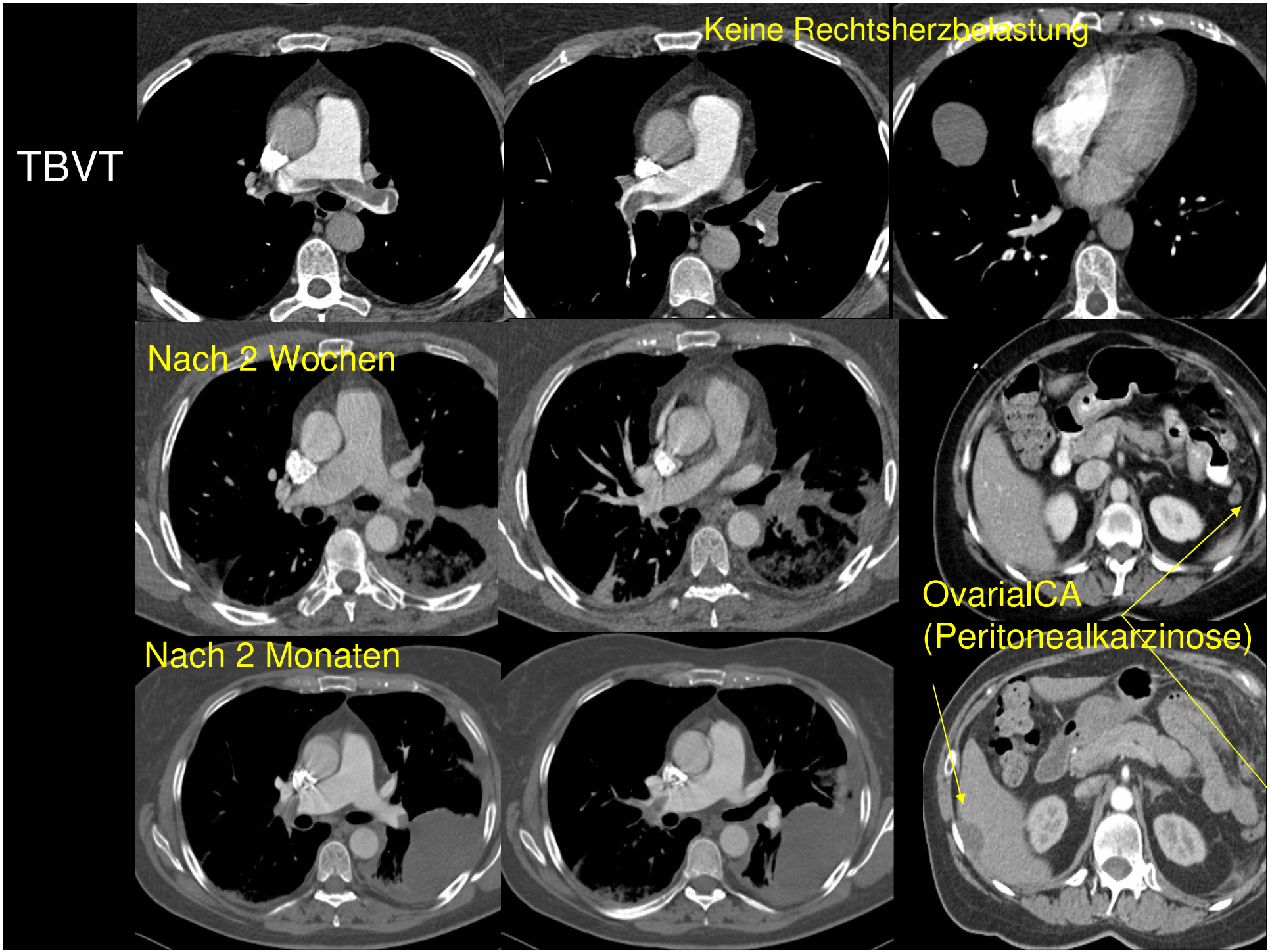
TBVT
Keine Rechtsherzbelastung
Nach 2 Wochen
Nach 2 Monaten
OvarialCA
(Peritonealkarzinose)

Lungenarterienembolie

Bei TBVT - gar mit LAE - ohne Ursache sollte ein paraneoplastisches Syndrom ausgeschlossen werden.

=> Tumorausschluß

- ♀ CT und Mammographie
- ♂ CT und PSA-Wert

Sentinel Lymphe Node (SLN) (Wächter LK)

Durch Früherkennung niedrige Vortest-Wahrscheinlichkeit für Streuung

=>

SLN-Biopsie statt komplette axilläre LK-Ausräumung

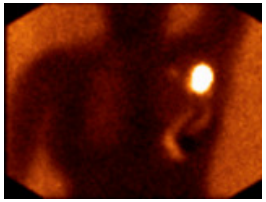

SLN statt Lymphödem

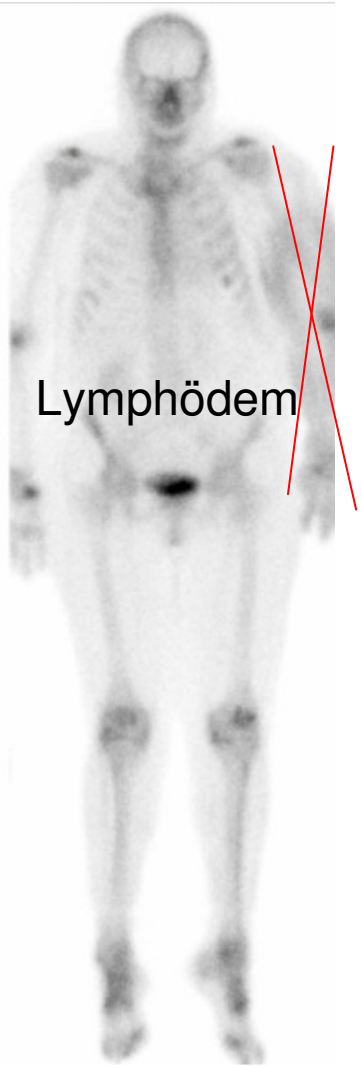

Mammographie-Screening

Sentinel Lymphe Node (SLN)

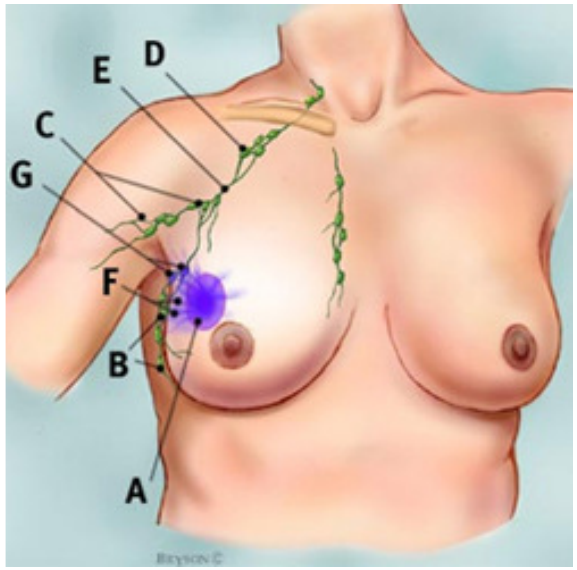

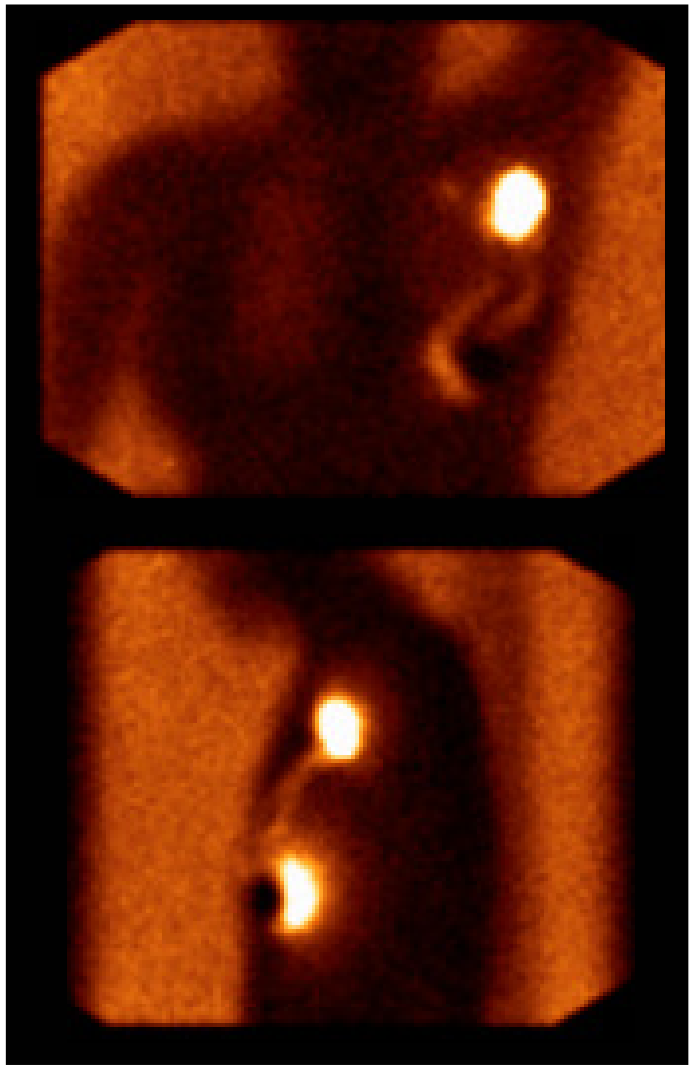

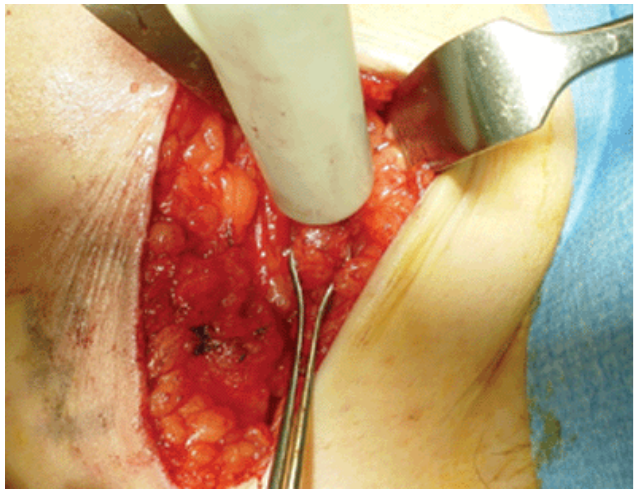

SD-Szinitigraphie

Pertechnetat

+

^{99m}Tc ($T_{1/2}$=6 h)

40 MBq

+

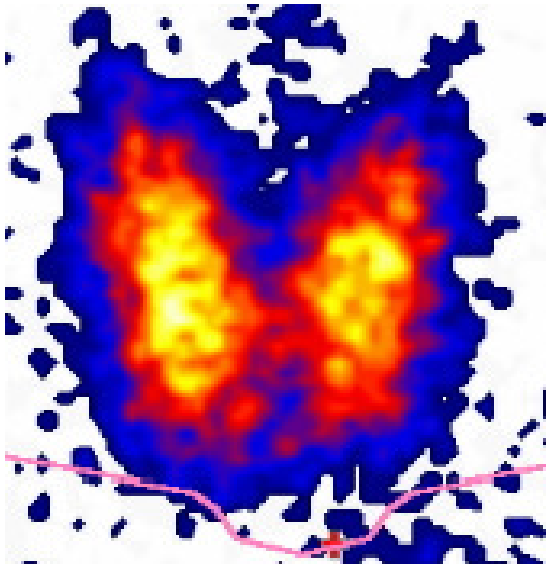

TSH supprimiert (<0.01mU/l)

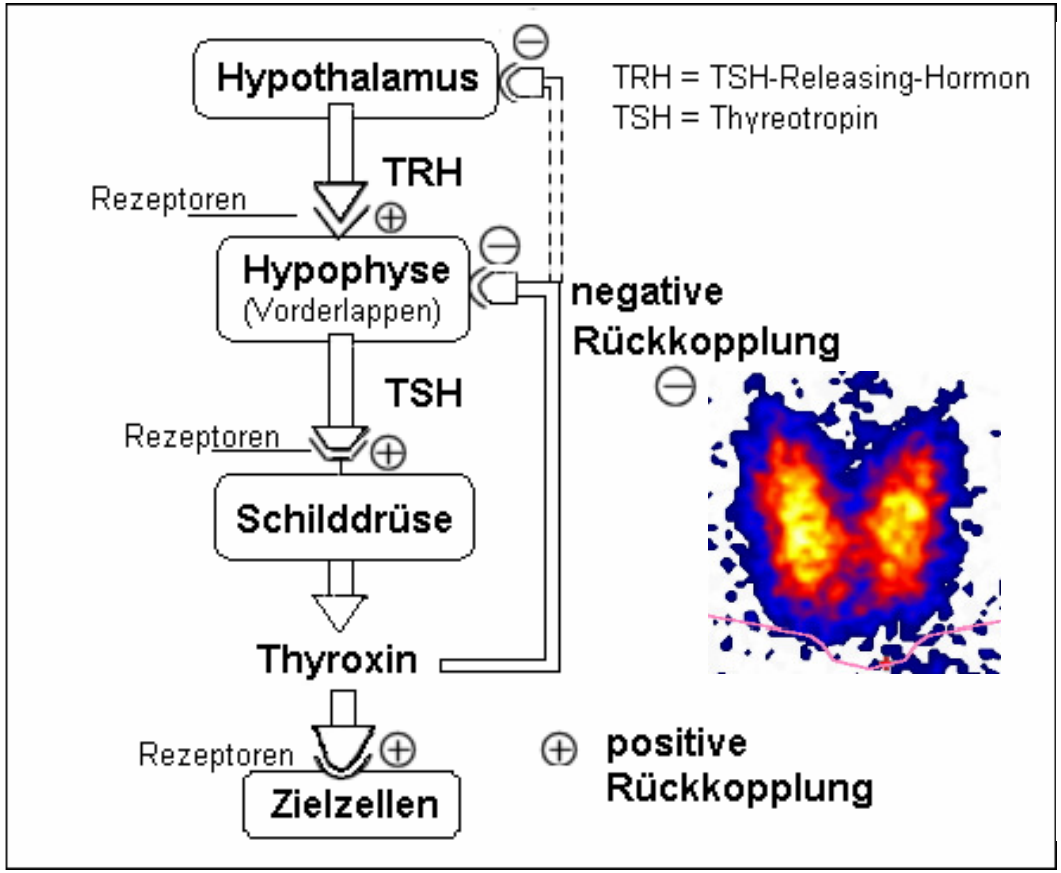

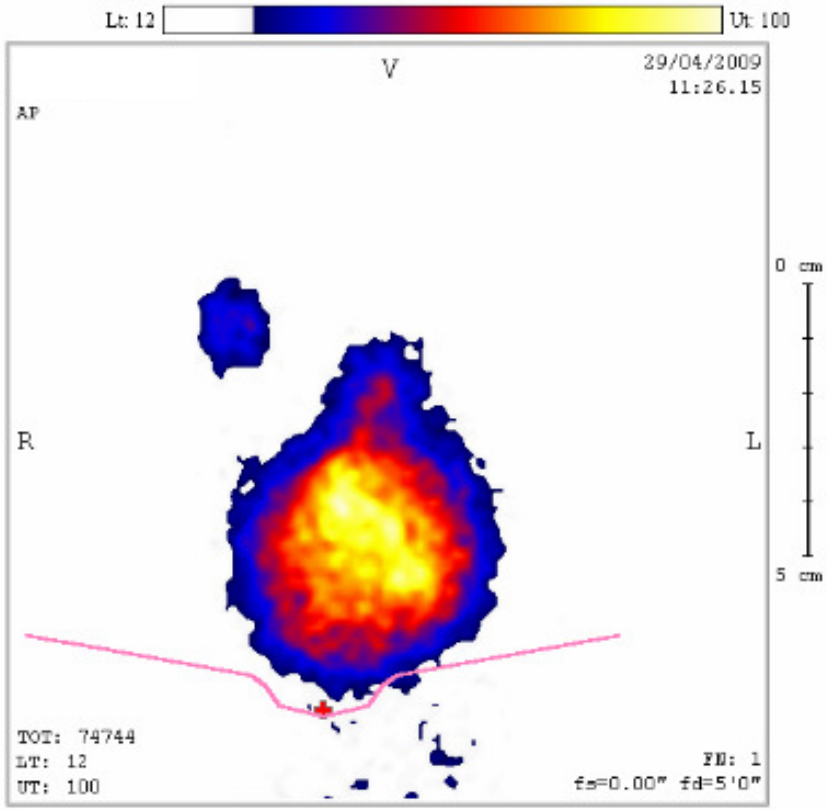

Knoten

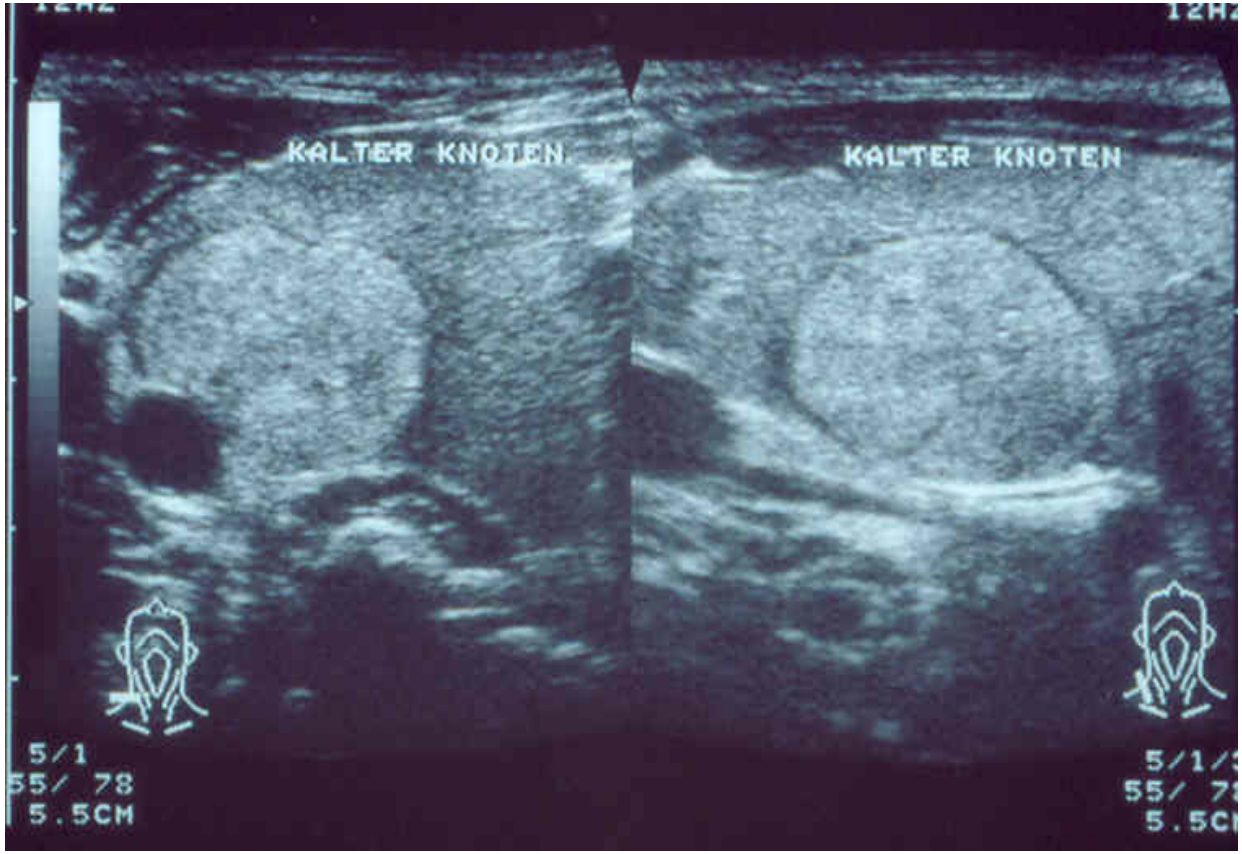

=> TSH ?

TSH supprimiert (<0.01mU/l)

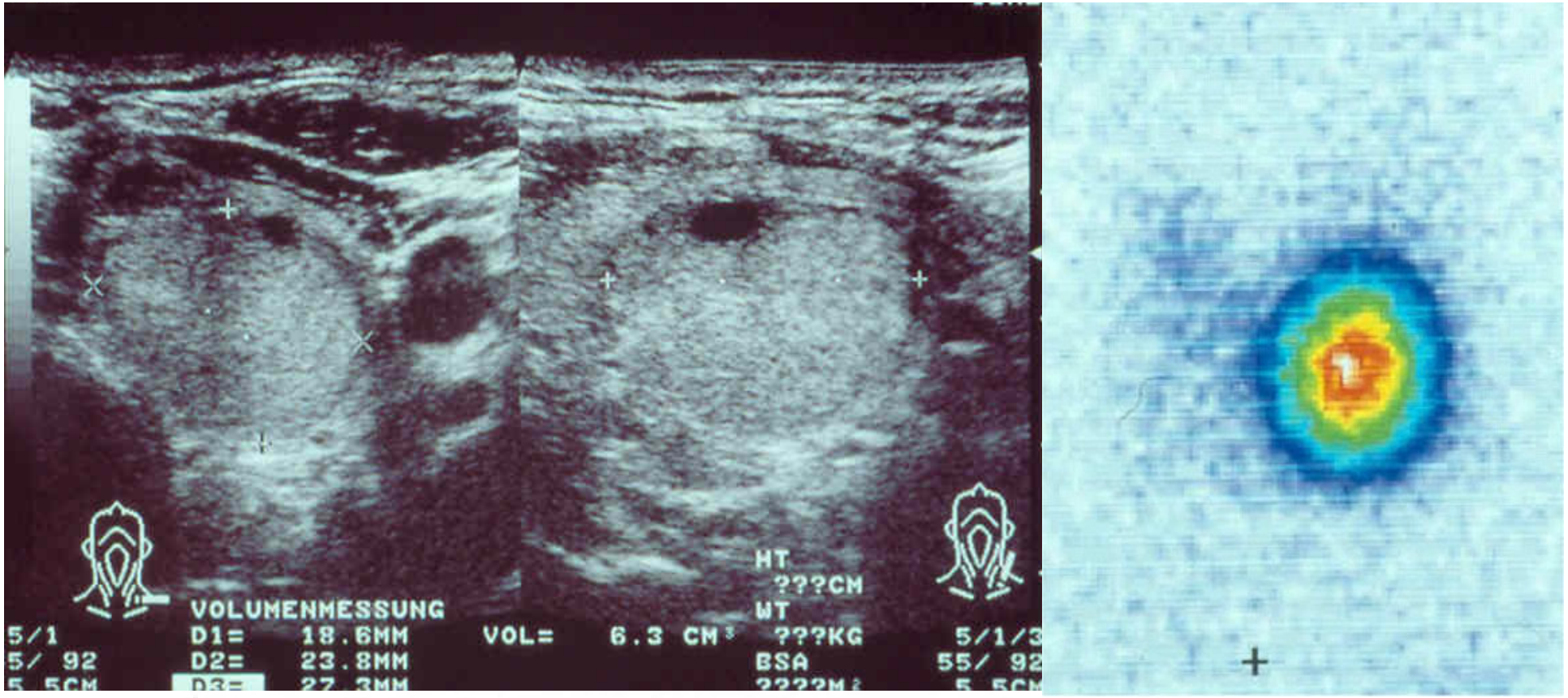

heiß

=> Autonomes Adenom => Radioiodtherapie (RIT)

TSH normal

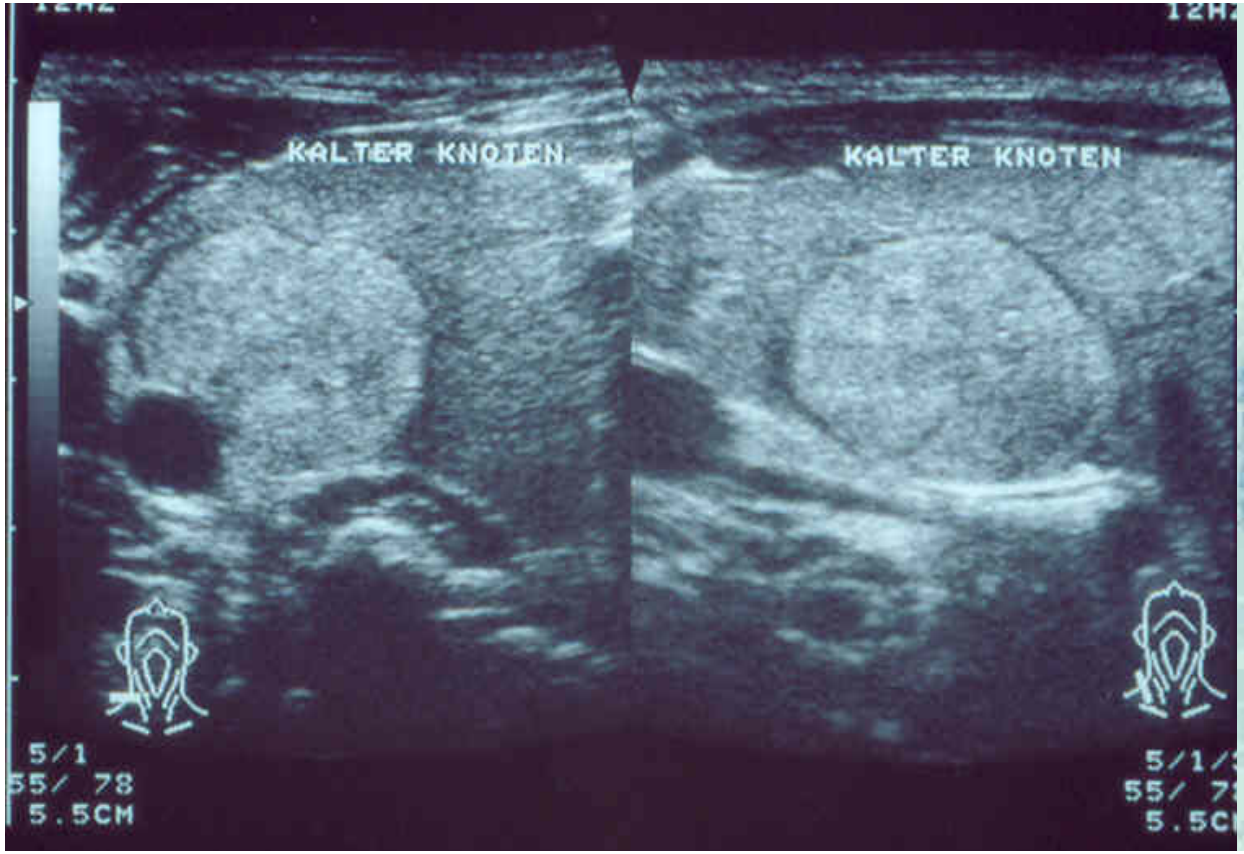

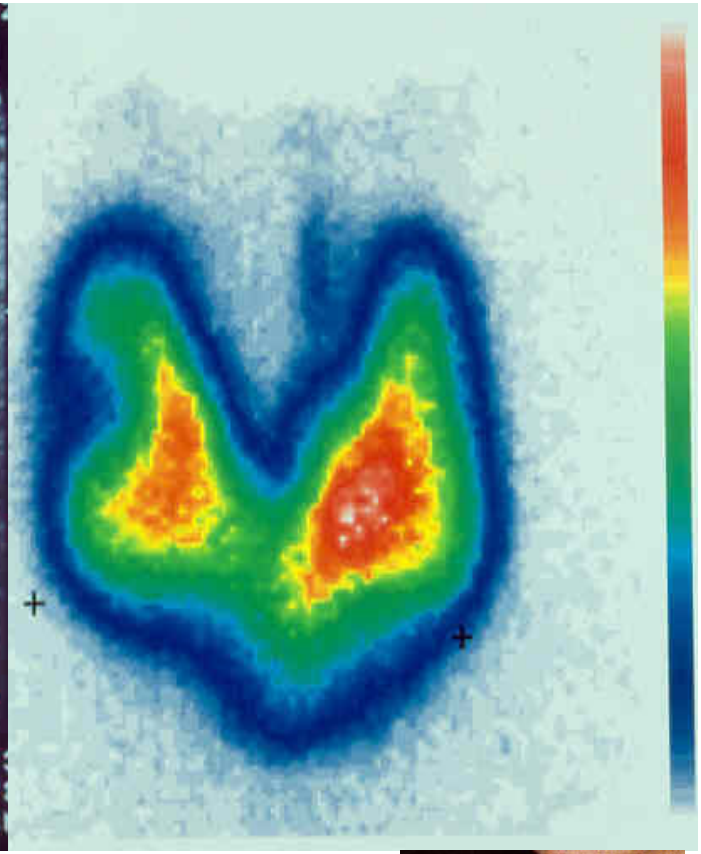

kalt

=> Feinnadelbiopsy (FNP)

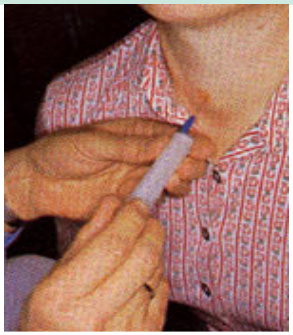

γ

TSH supprimiert (<0.01mU/l)



=>

ß-Blocker
+ Nikotinkarenz
+ Radioiodtherapie (RIT)

M. Basedow (SD-Autoantikörper (TRAK) positiv)

β^+-Diagnostik

Gammakamera / SPECT

PET/CT



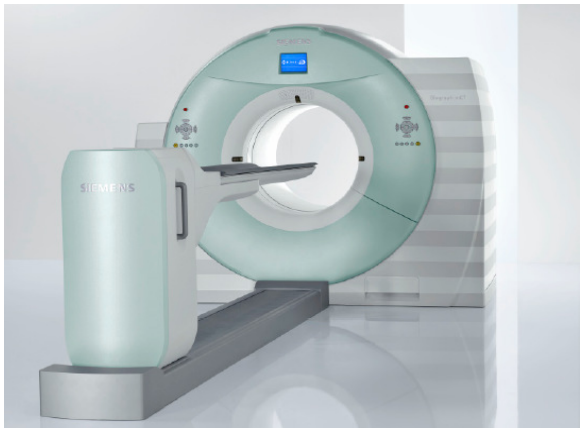

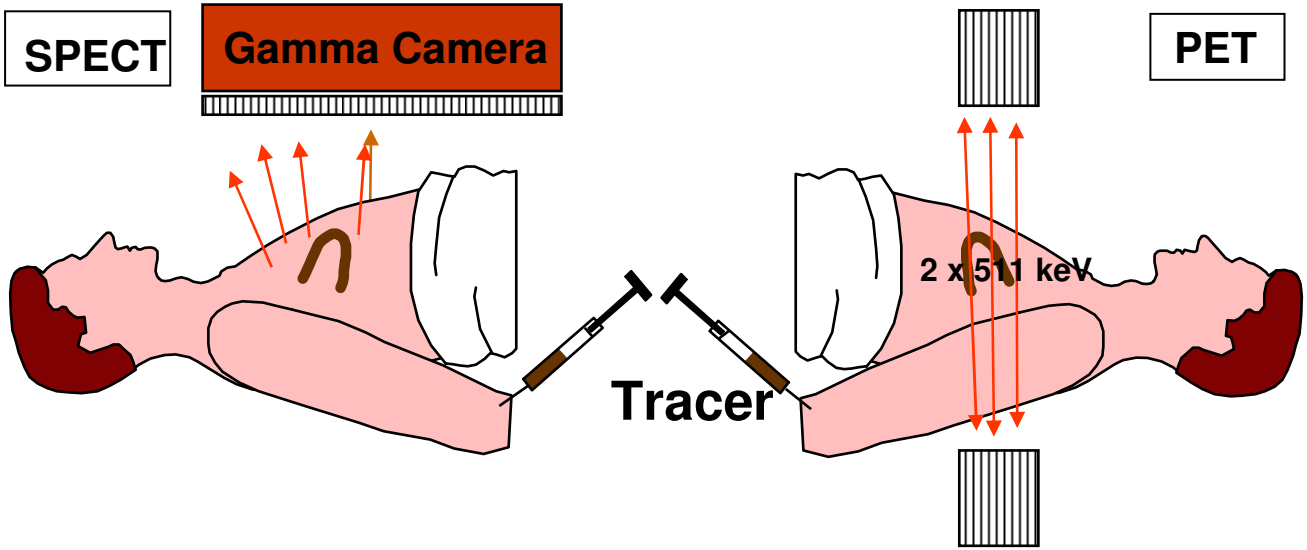

Positronen-Emissions-Tomographie (PET)/CT



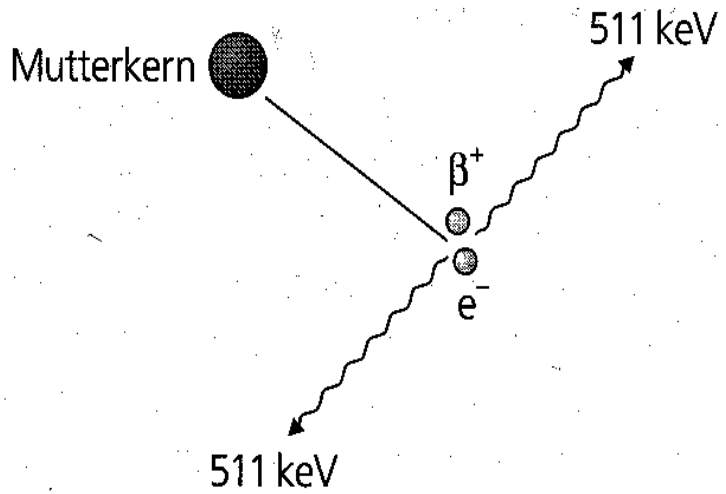

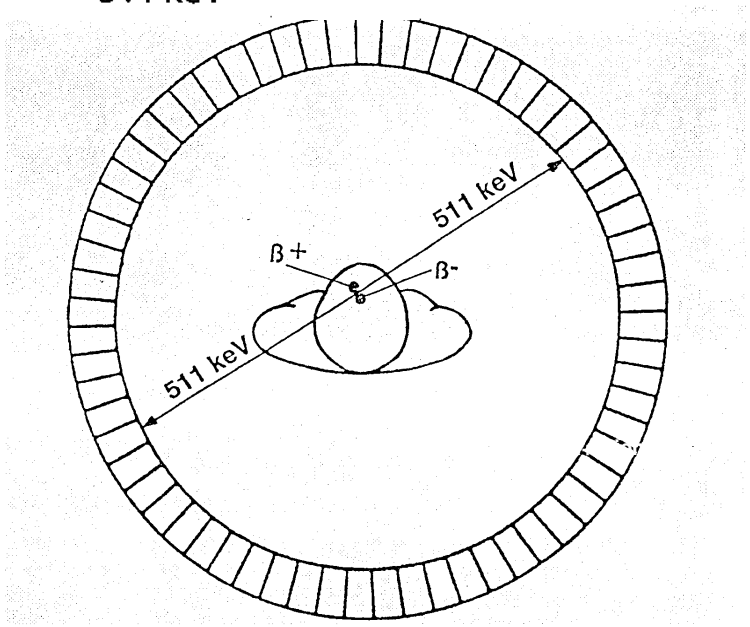

$$E=mc^2=h\nu=eU$$

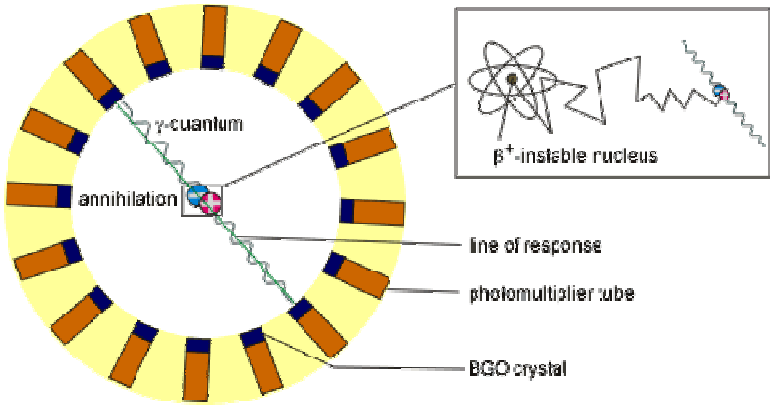

Positronen-strahler	HWZ	Produkt	max. Energie des Positrons	max. lineare Reichweite	mitt. Lineare Reichweite
	min		MeV	mm	mm
^{11}C	20,4	^{11}B	0,96	5,0	0,3
^{13}N	9,9	^{13}C	1,19	5,4	1,4
^{15}O	2,1	^{15}N	1,72	8,2	1,5
^{18}F	110	^{18}O	0,64	2,4	0,2
^{68}Ga	68	^{68}Zn	1,89	9,1	1,9
^{82}Rb	1,3	^{82}Kr	3,35	15,6	2,6

$$ {}^{A}_{Z}X \longrightarrow {}^{A}_{Z-1}Y + \beta^+ + \nu $$

^{18}F-FDG: Wirkungsprinzip

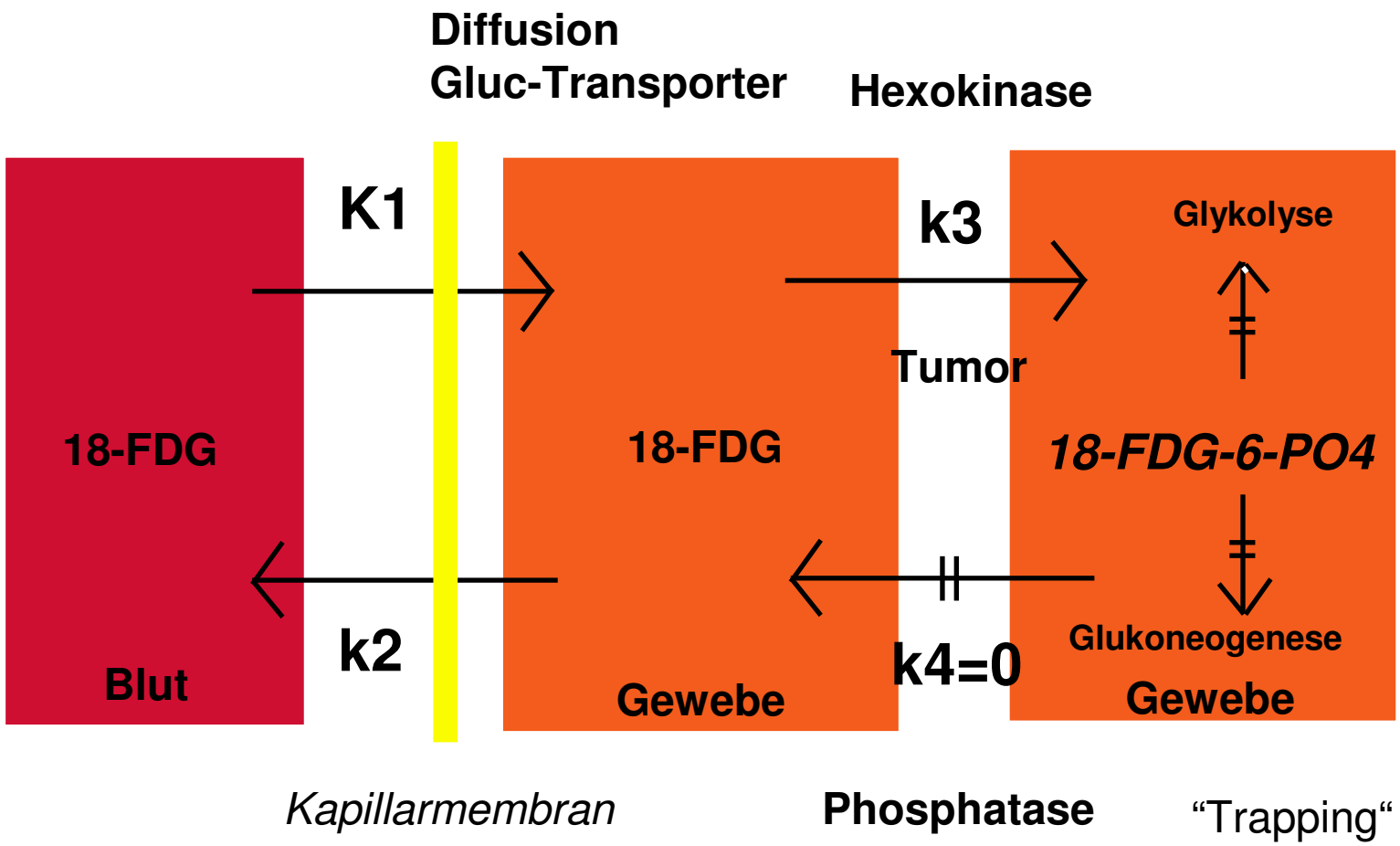

Arterielle Gefäße | **Freie Glukose im Gewebe** | **Phosphorylierte Glukose im Gewebe**

β^+

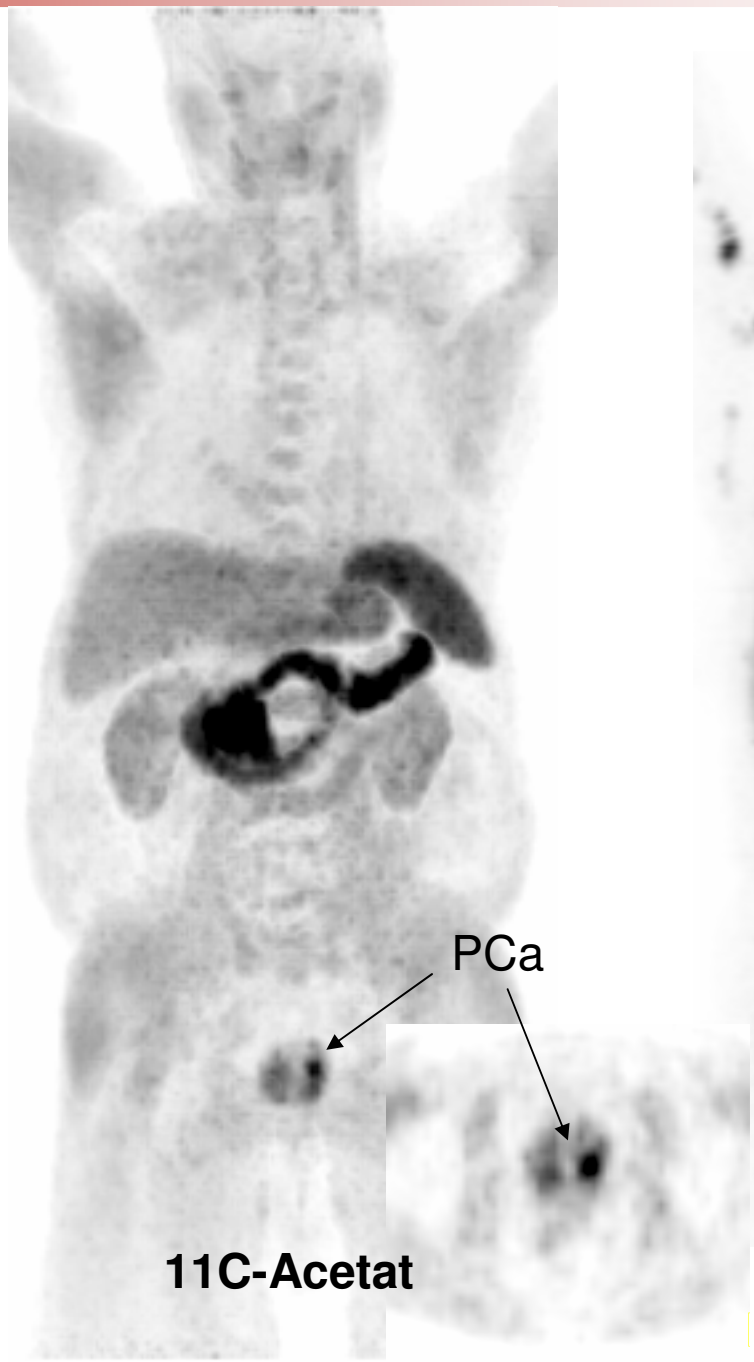

Pulmonaler Rundherd

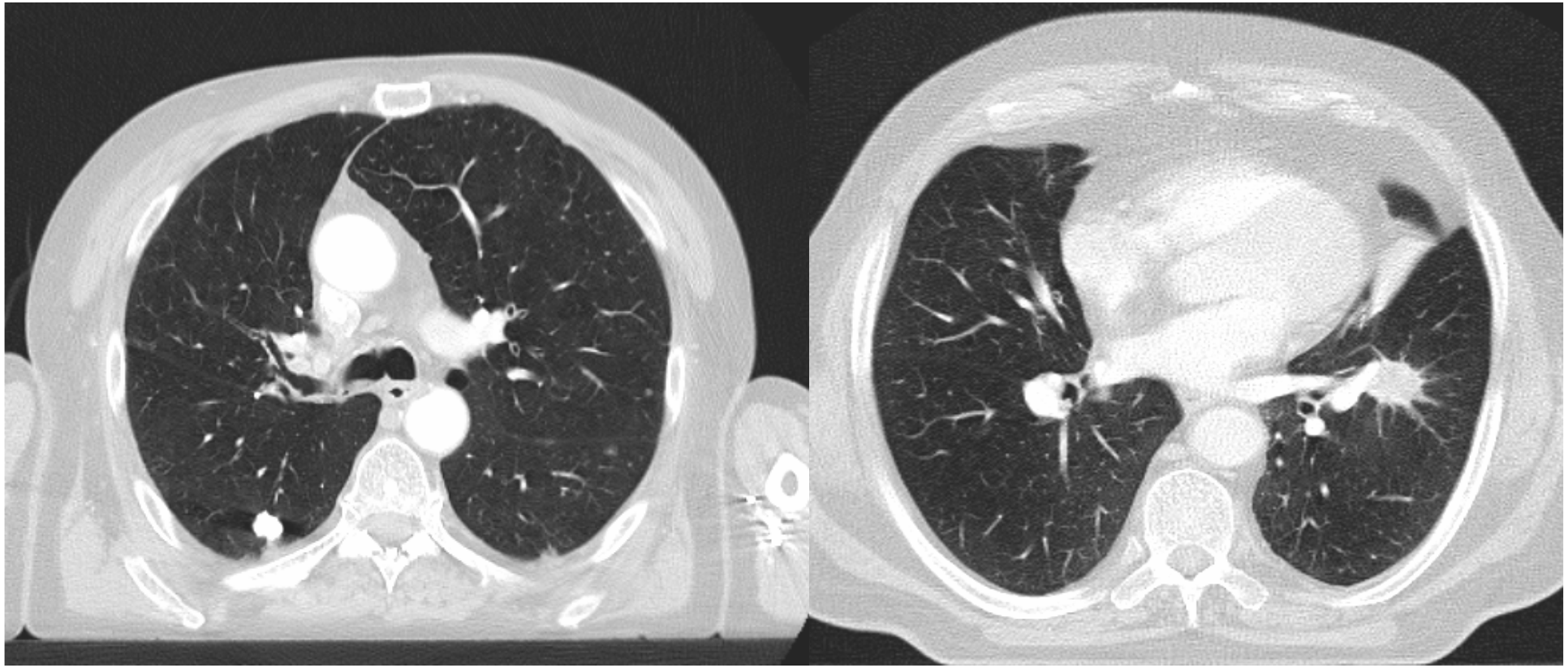

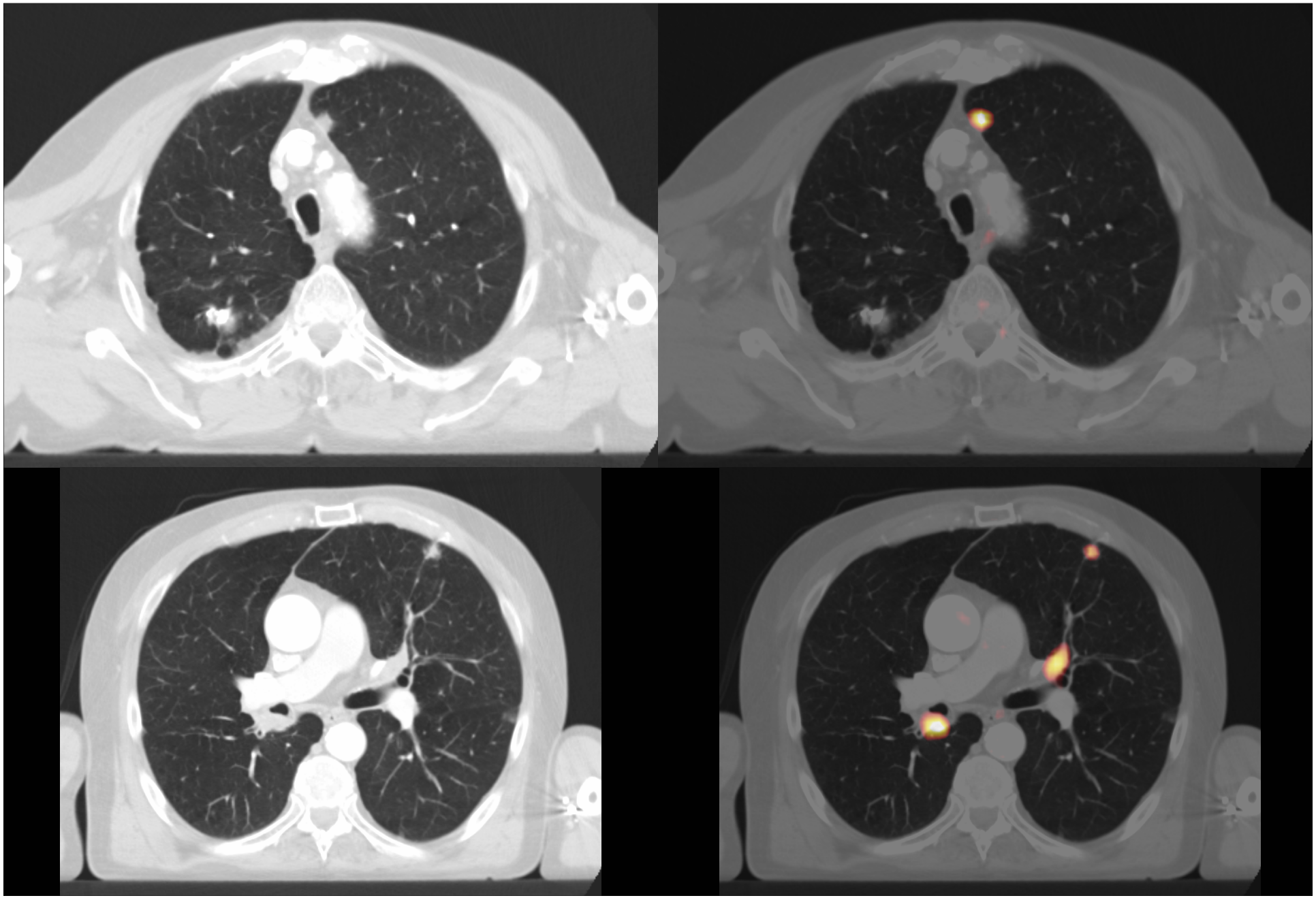

PET: PPV>>>>>NPP

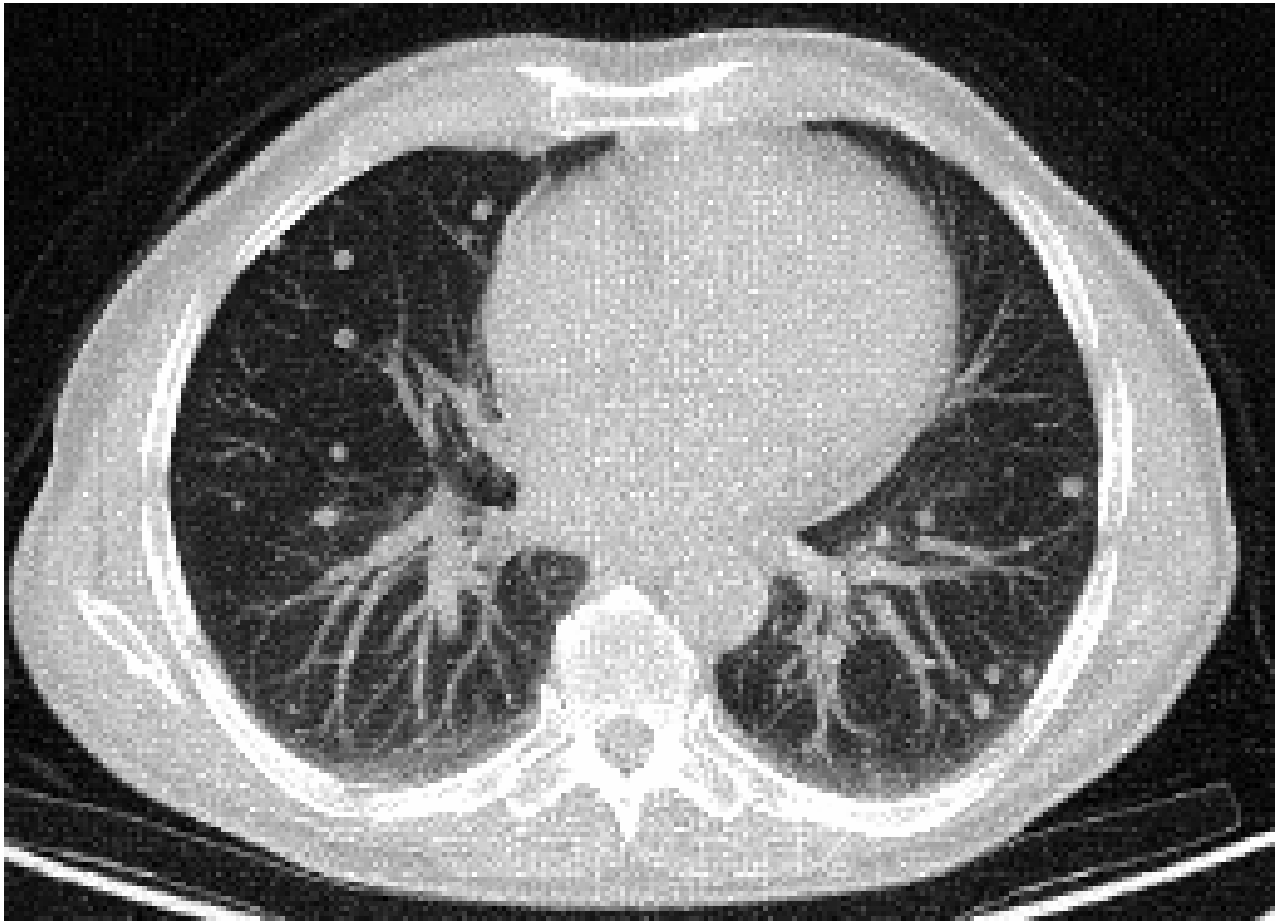

Nicht alles, was nicht FDG speichert,ist nicht maligne

N-Staging

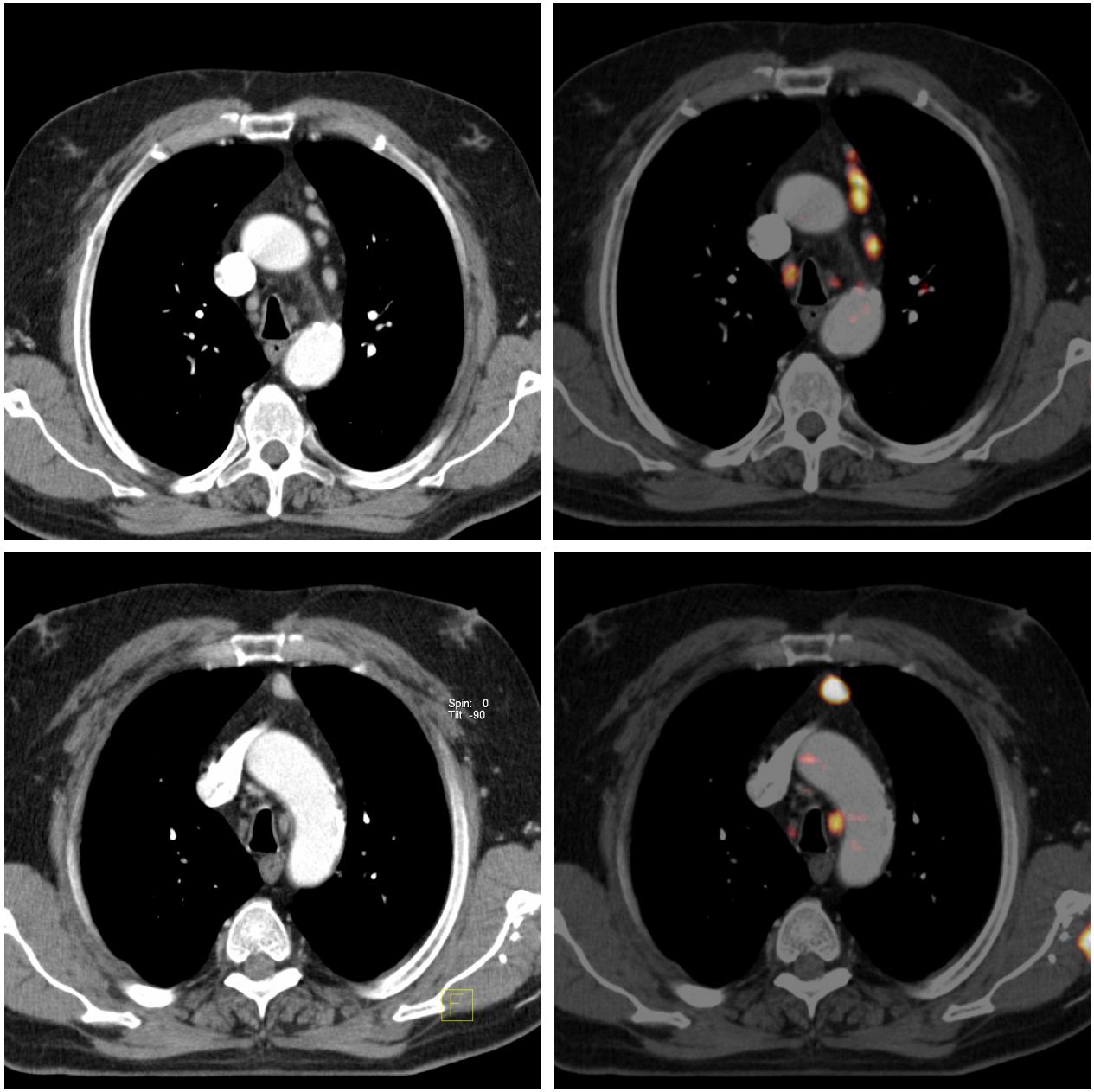

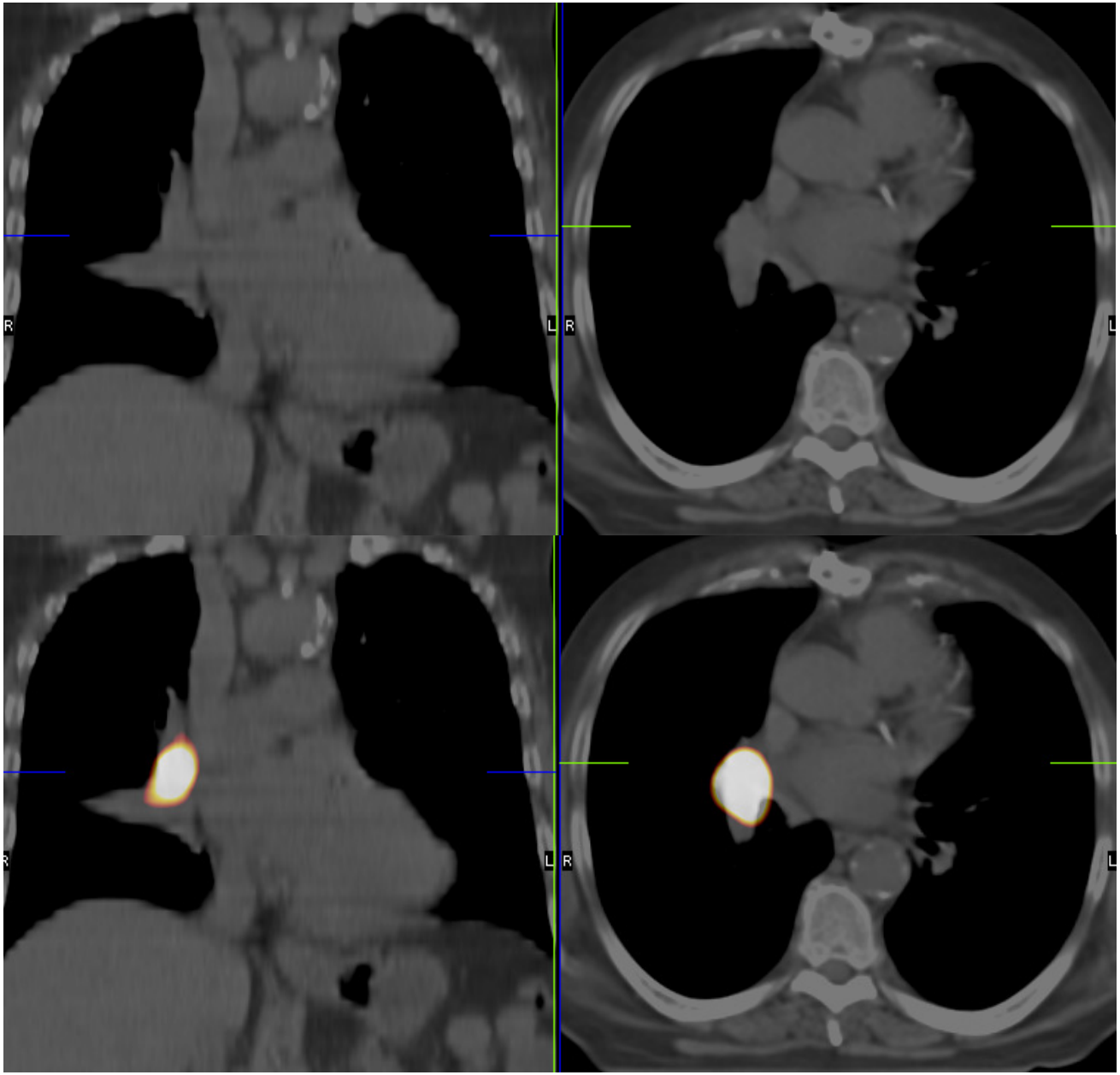

NSCLC
mit Atelektase

Bestrahlungsplanung

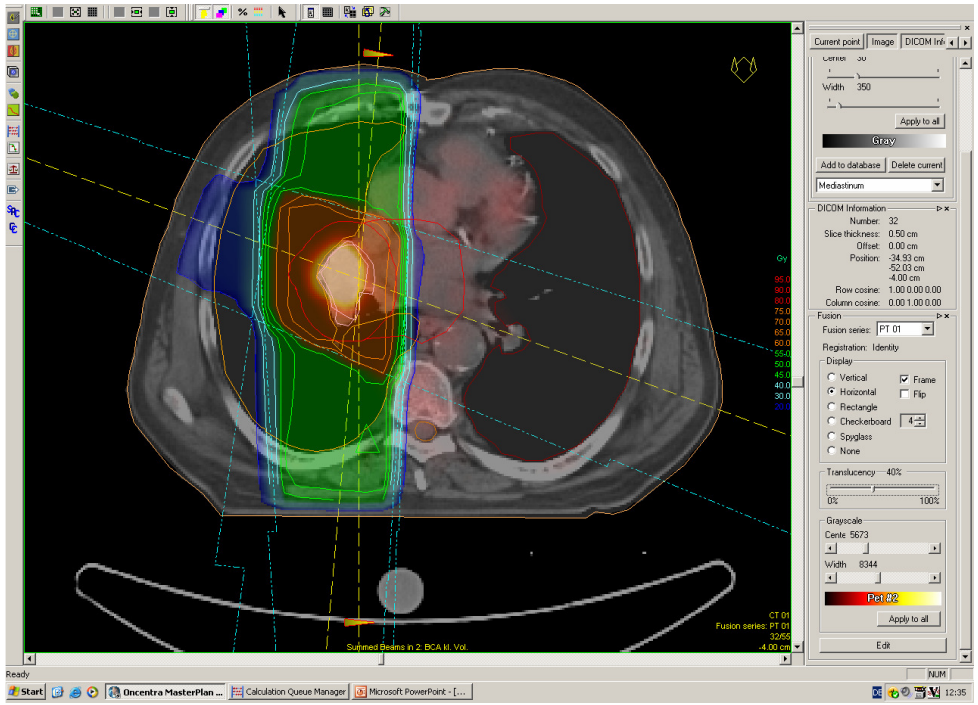

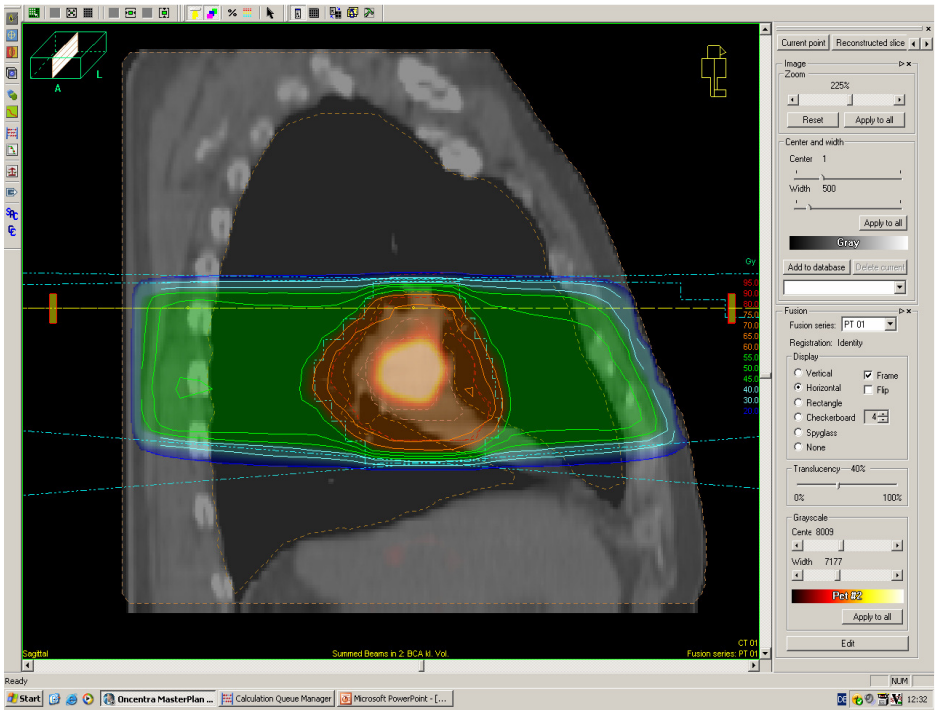

Malignes Melanom

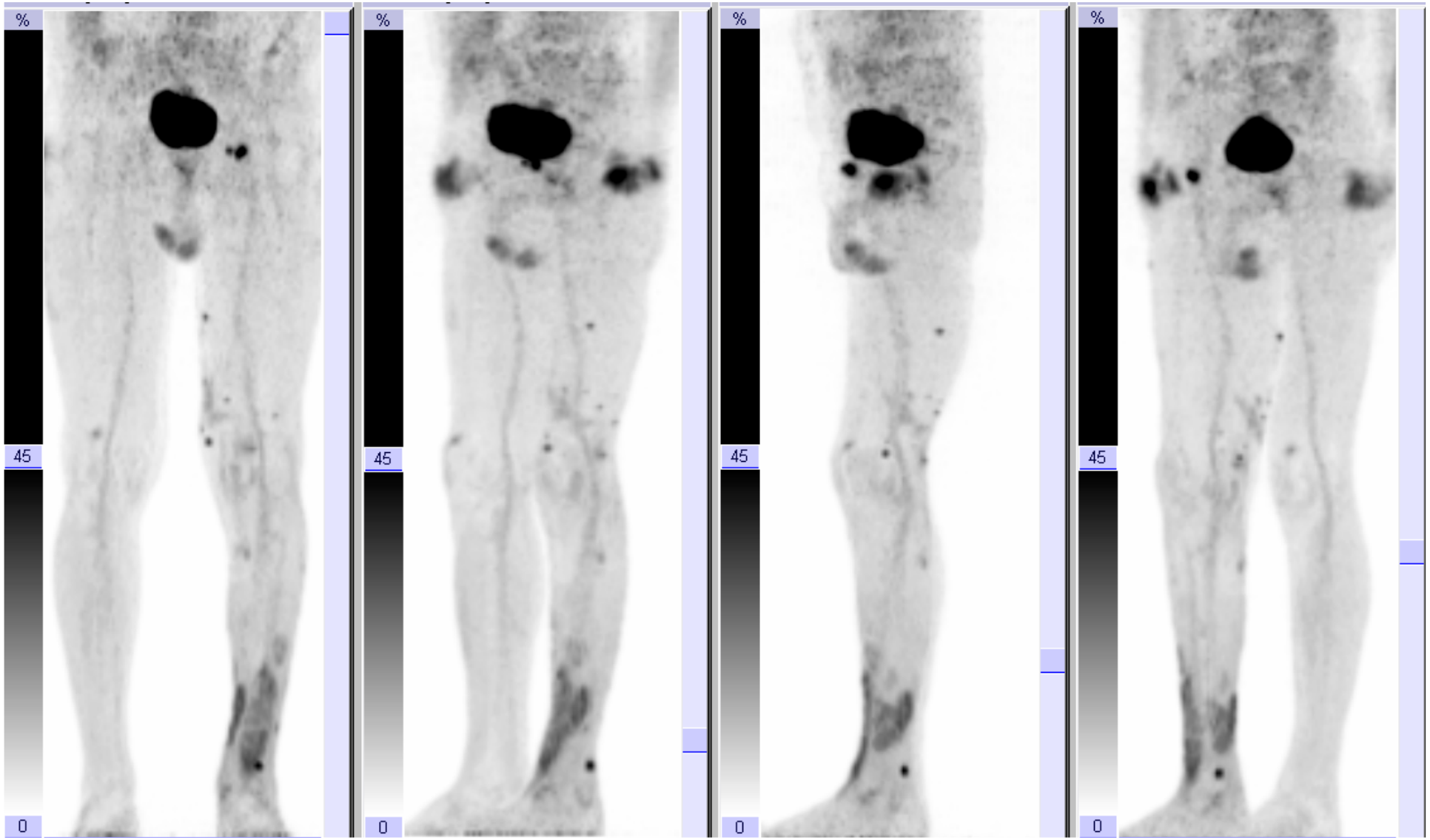

MM

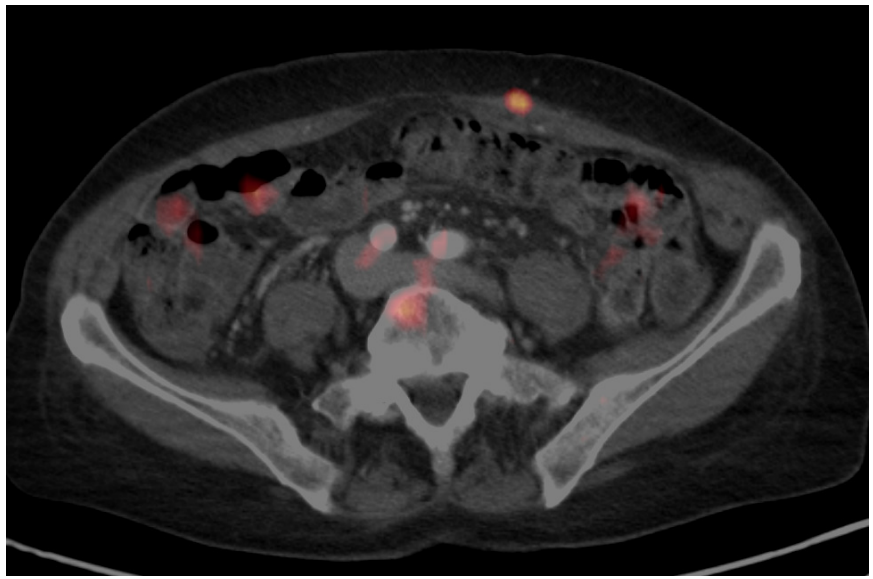

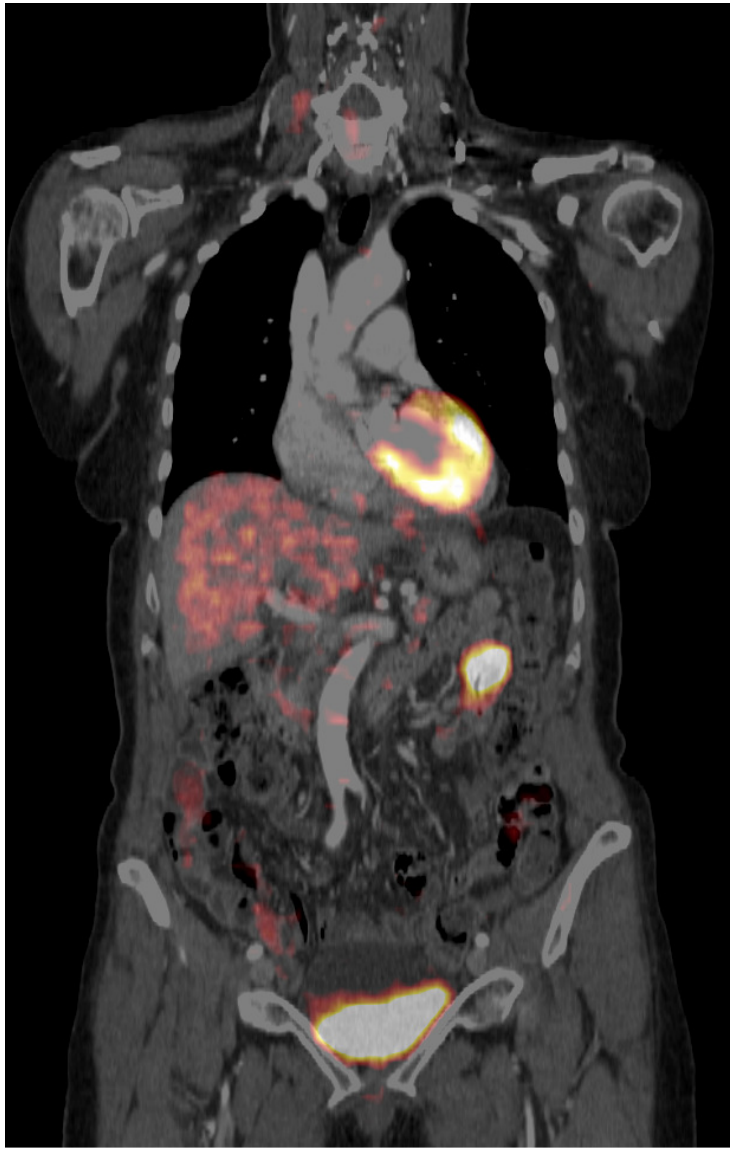

Barrett-CA

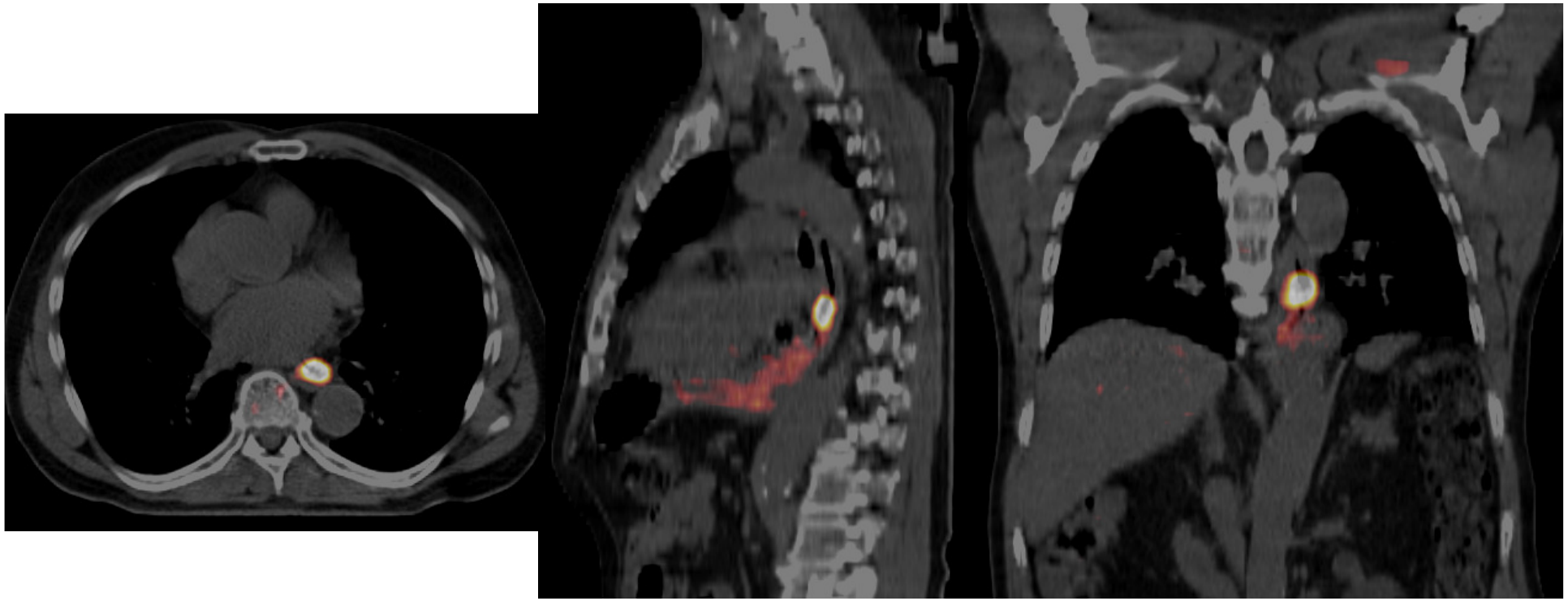

ÖsophagusCA

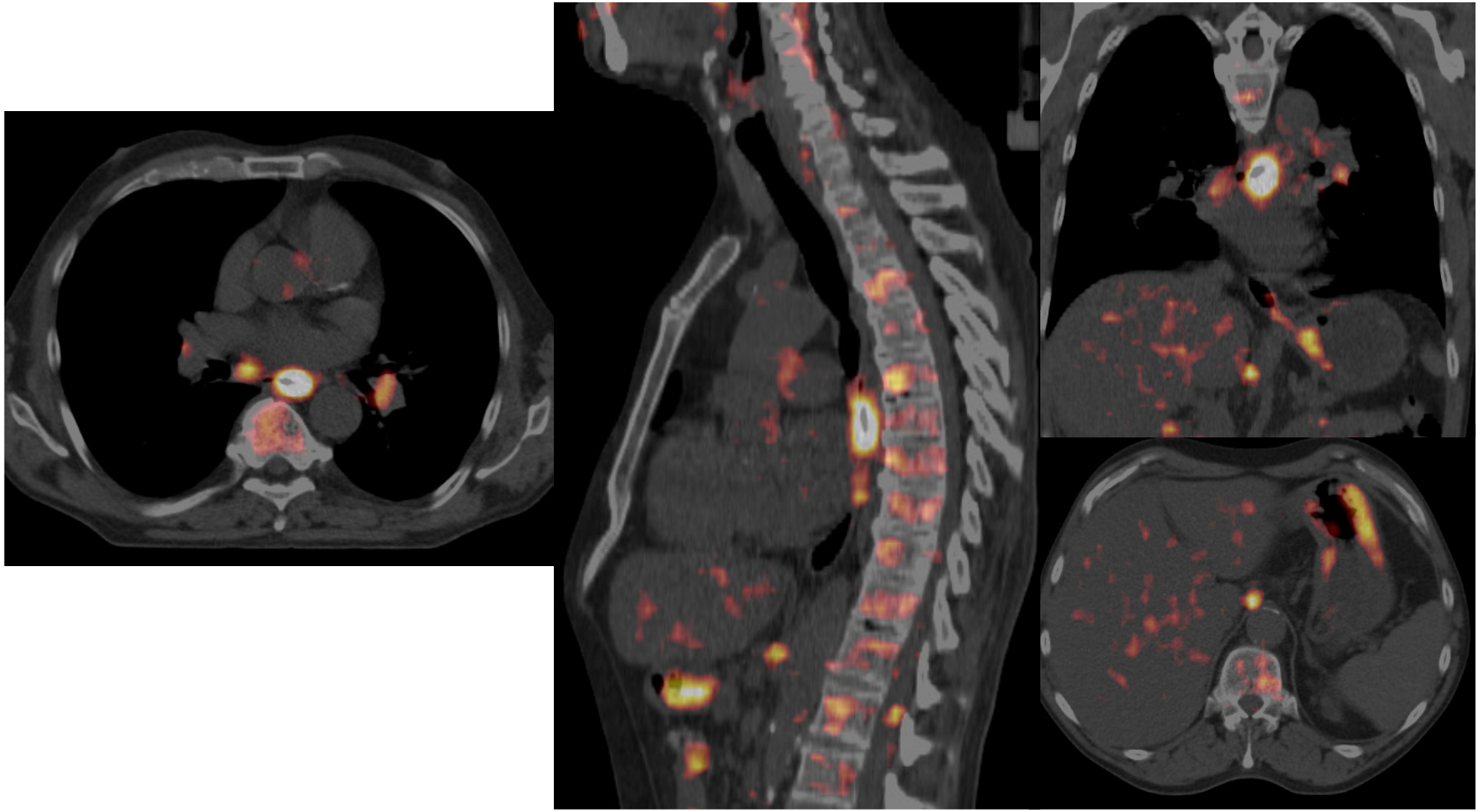

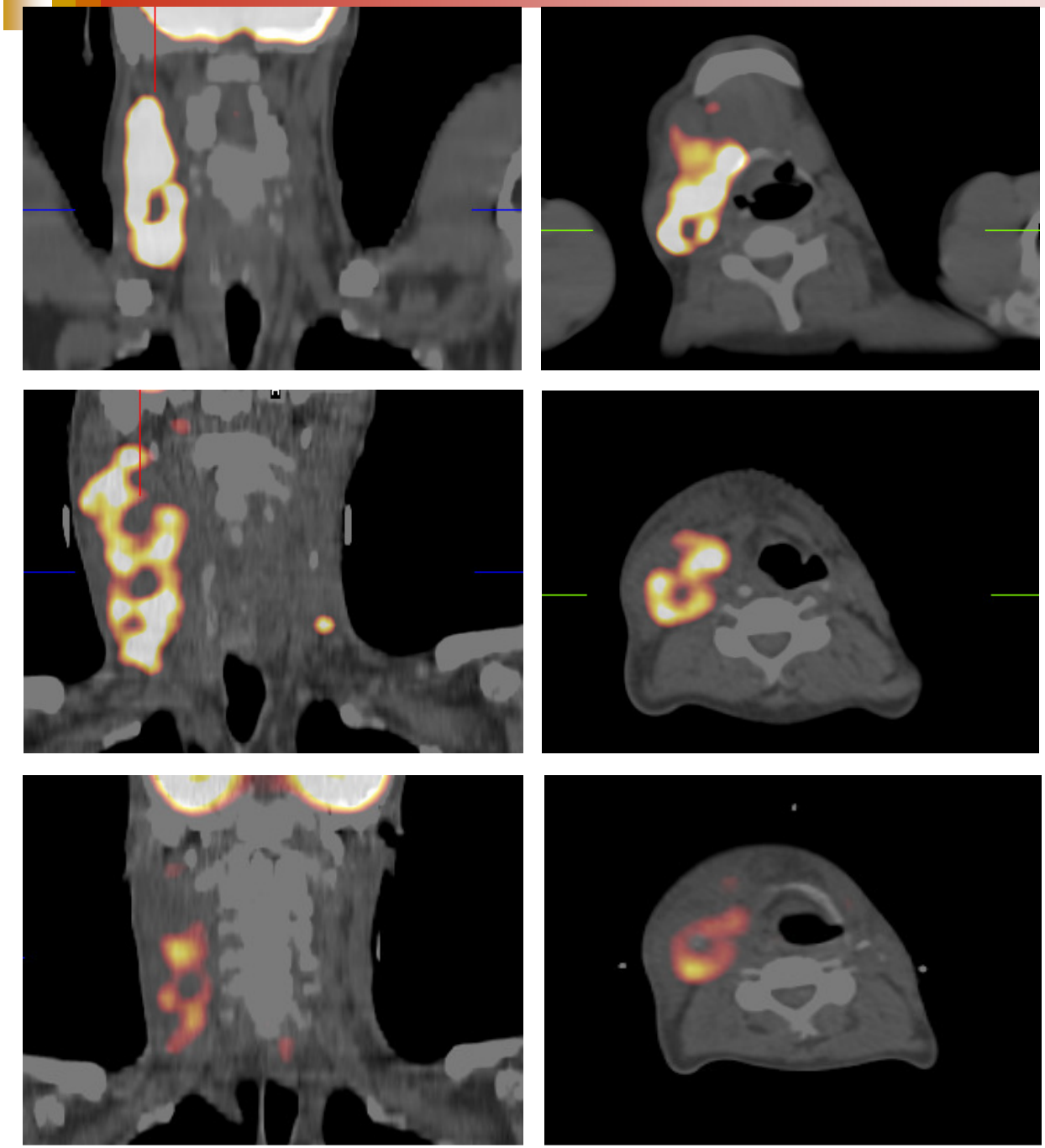

HypopharynxCA

Initial-Staging

RCx

Restaging n. 2 Wo

Restaging n. 6 Wo

Lokalrezidiv PCA
C-11-Acetat- PET/CT

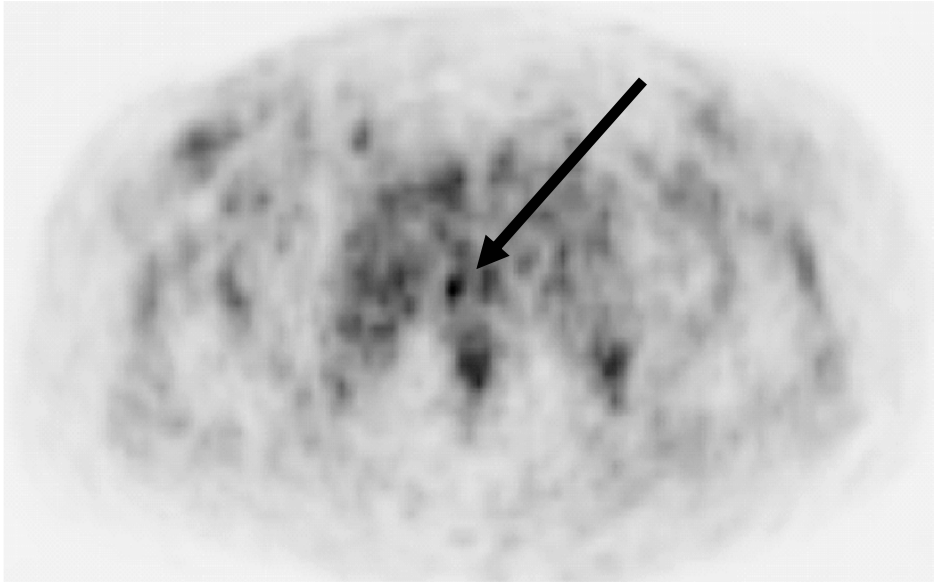

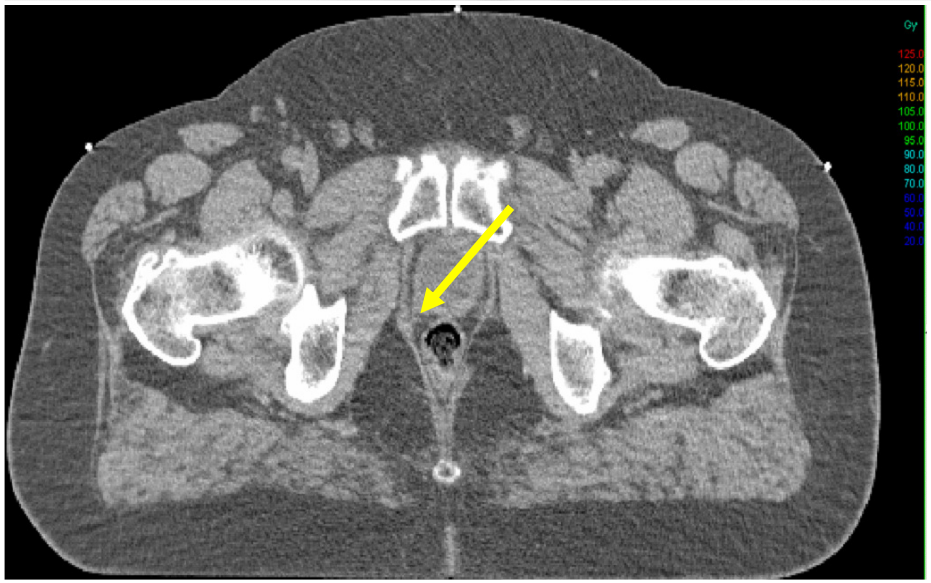

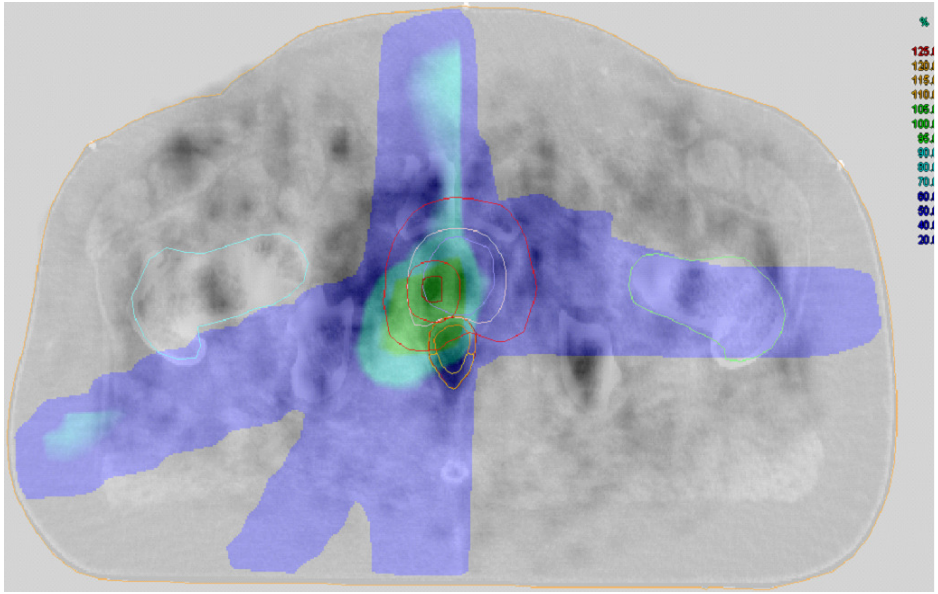

β^--Therapie

RIT benigner SD-Erkrankungen

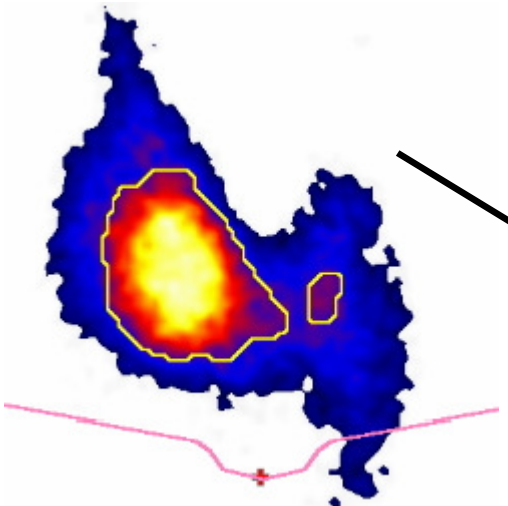

Unifokale Autonomie

Ziel

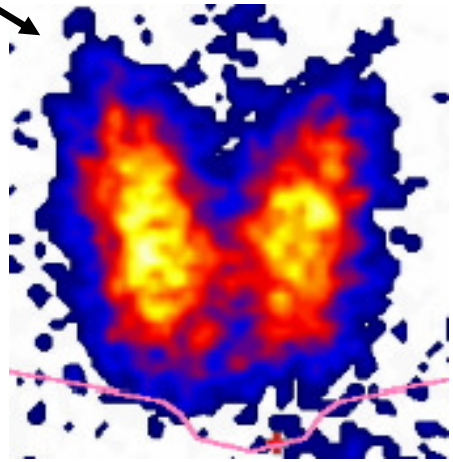

Eurthyreose

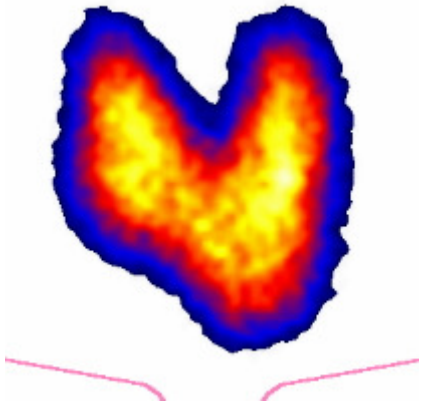

M. Basedow

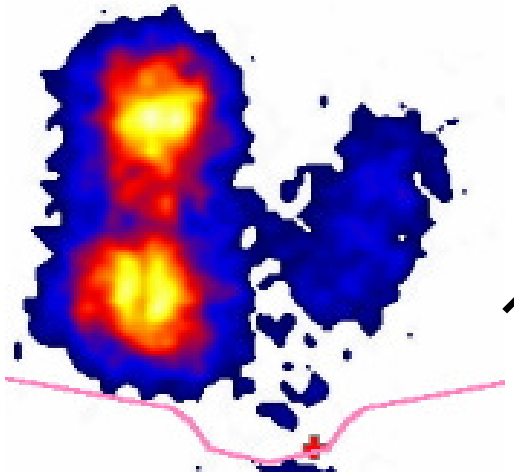

Bifokale Autonomie

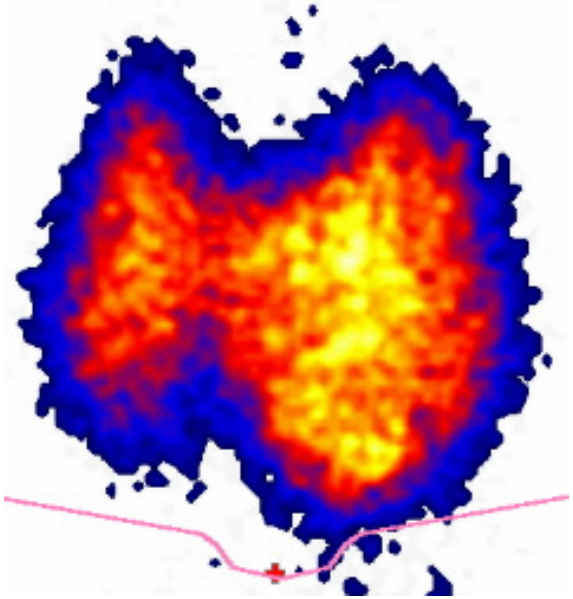

Struma / disseminierte Autonomie

RIT maligner SD-Erkrankungen

- Hintergrund:
  - Ablation aller SD-Zellen 3-5 Wochen post OP
  - NM-Initial-Staging/Restaging
  - Tumormarker Thyreoglobulin (TG) nur verwertbar nach SD-Ablation (nicht nachweisbar)

- Zu beachten:
  - Absolute Kontraindikation: Schwangerschaft
  - Abgeschirmt (stationär) auf „Isolierstation“
    - I131 (T1/2 = 8 d, ß-Strahler)
      (vs. Diagnostik: ^{99m}Tc T1/2 = 6 h, γ-Strahler)
    - 3700 MBq (Diagnostik: 40 MBq)
  - TSH > 80 mU/L durch
    - endogene Stimulation durch post-OP Aussetzen der Hormon-Substitution (L-Thyroxin-Karenz)
    - exogen durch Gabe von synthetischem TSH

Radioiod-Ablation von SD-Restgewebe



RIT - Therapieverlauf

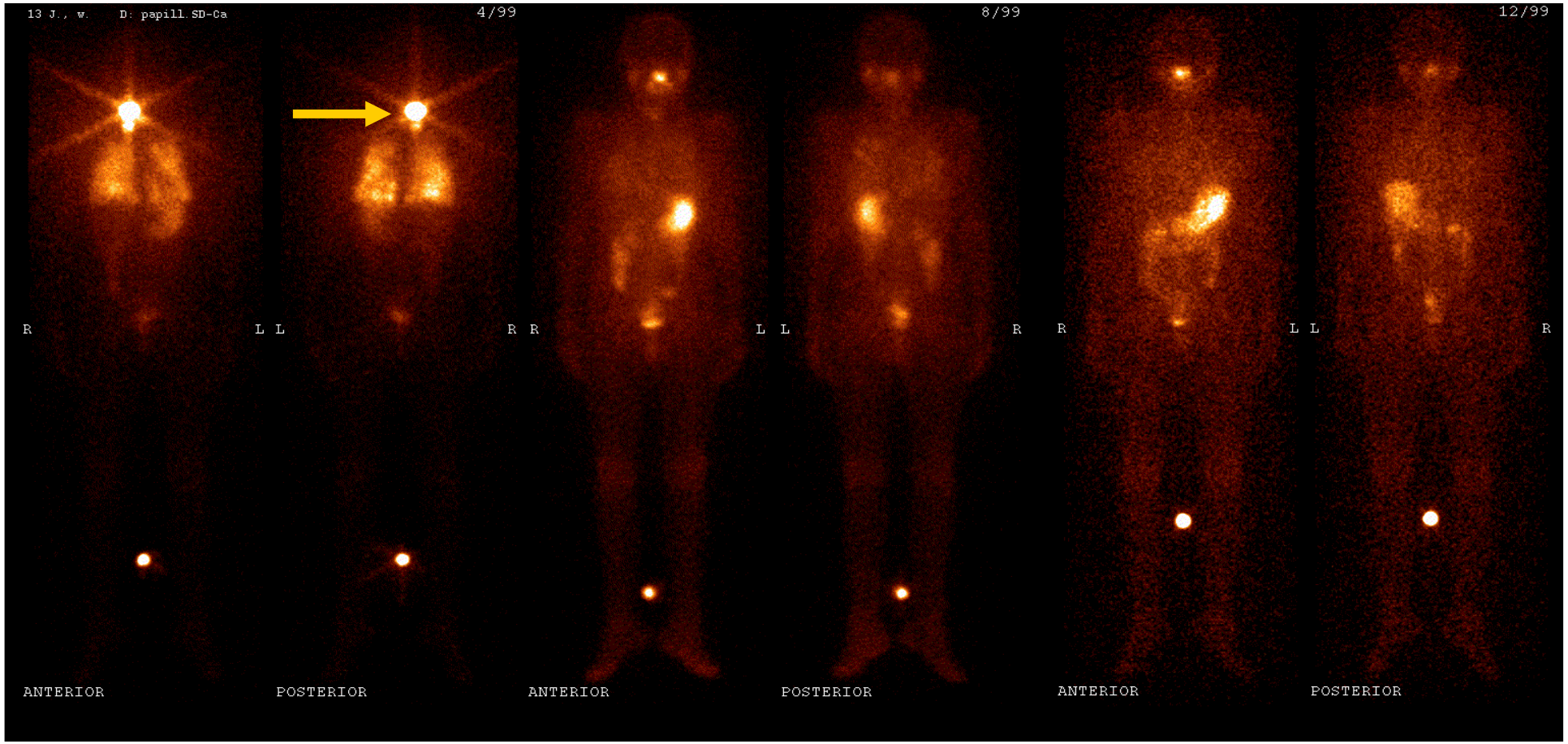

04 / 1999 **08 / 1999** **12 / 1999**

Papilläres Schilddrüsen-CA mit LungenMets

Radiosynoviorthese (RSO)

β^- (Elektronen)-Strahler (Reichweite: < 10 mm) + Glucokorticoid

RSO - Verwendete Isotope

	Gelenke	HWZ	Strah-lung	Reichweite	max. ß-Energie
^{90}Y	groß (Knie)	2,7 d	ß	3,6 (bis 11 mm)	2,26 MeV
^{186}Re	mittel	3,7 d	ß	1,2 (bis 3,7mm)	0,98 MeV
^{169}Er	klein	9,5 d	ß	0,3 (bis 1 mm)	0,34 MeV

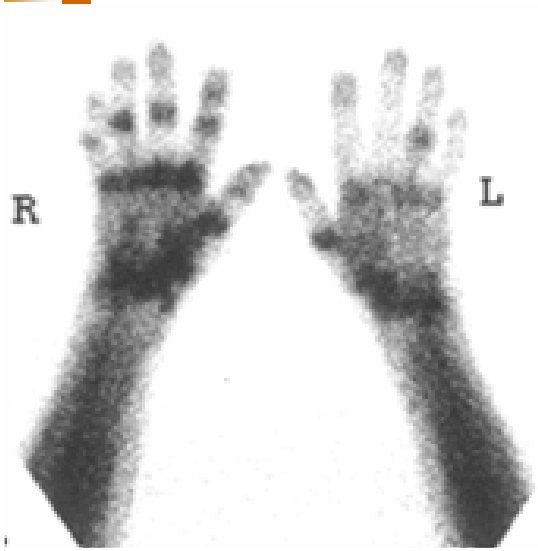

Joint Affected by
Rheumatoid Arthritis

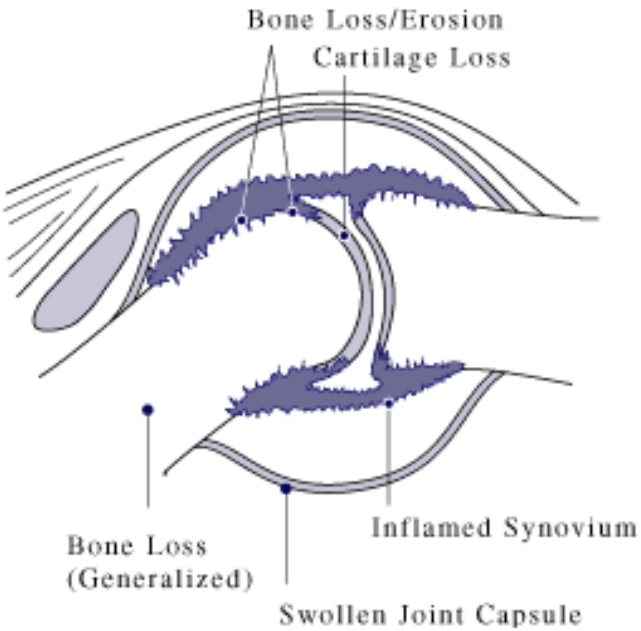

RSO - Ergebnisse

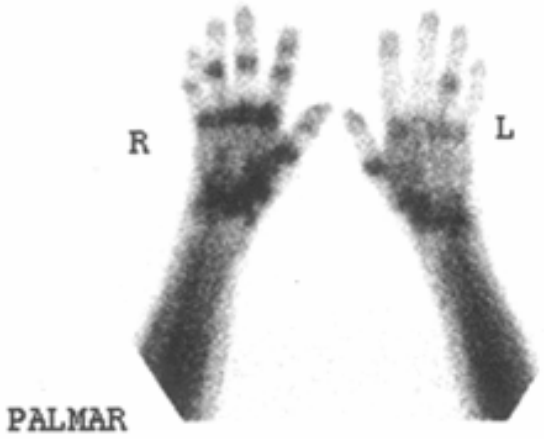

RSO

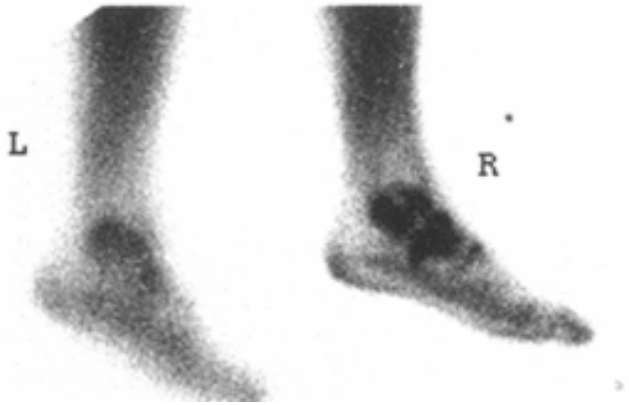

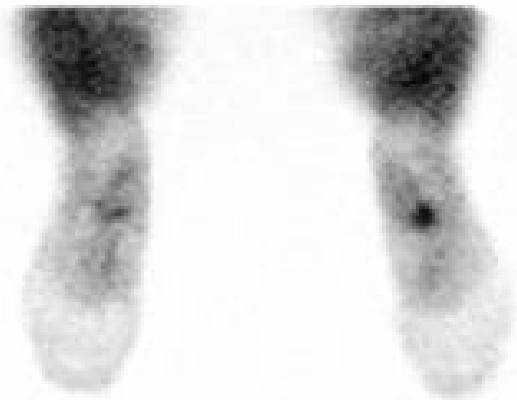

vorher

nachher

Selektive Interne Radiotherapie (SIRT) bei NET

PET/CTA

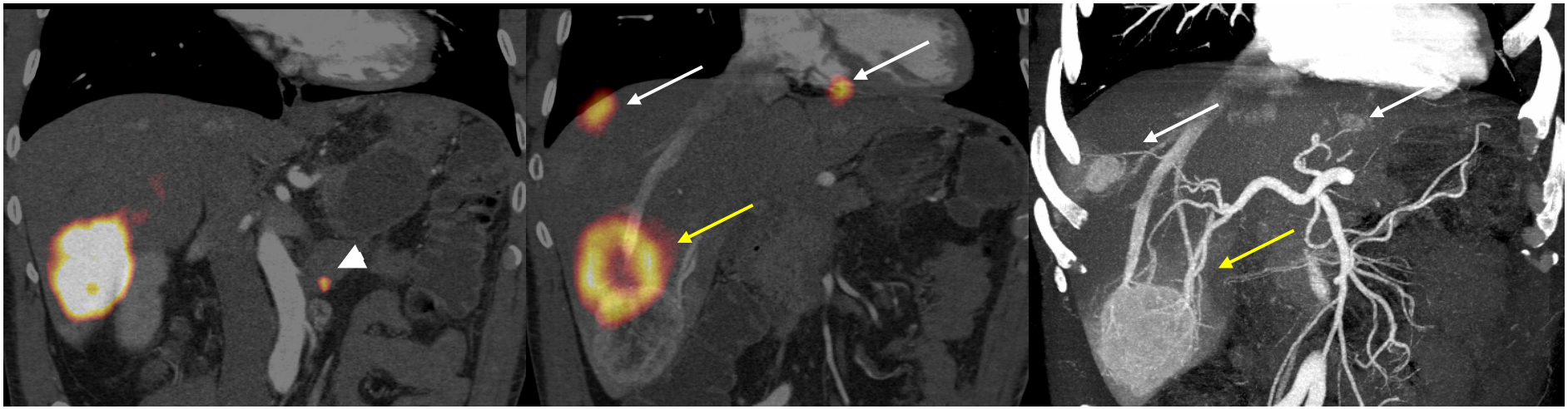

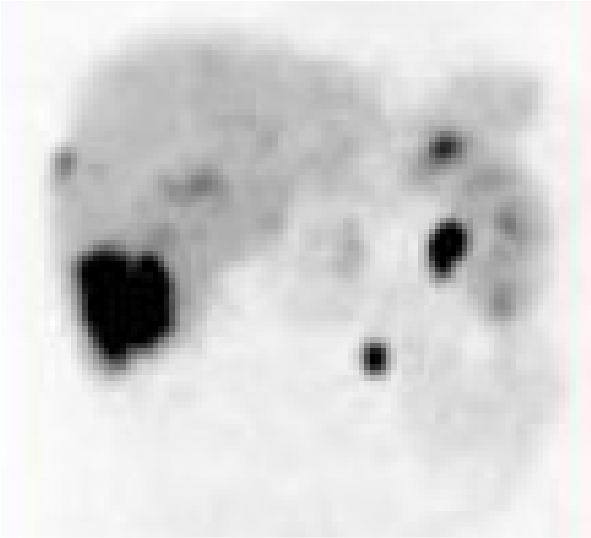

SIRT →

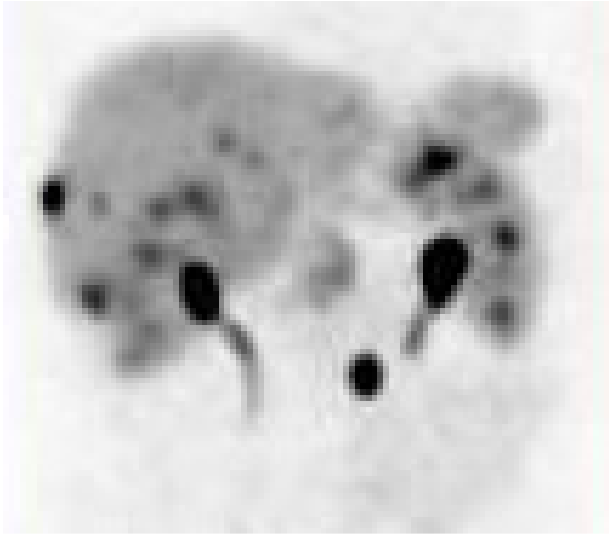

^{131}I-MIBG-Therapie bei Neuroblastom

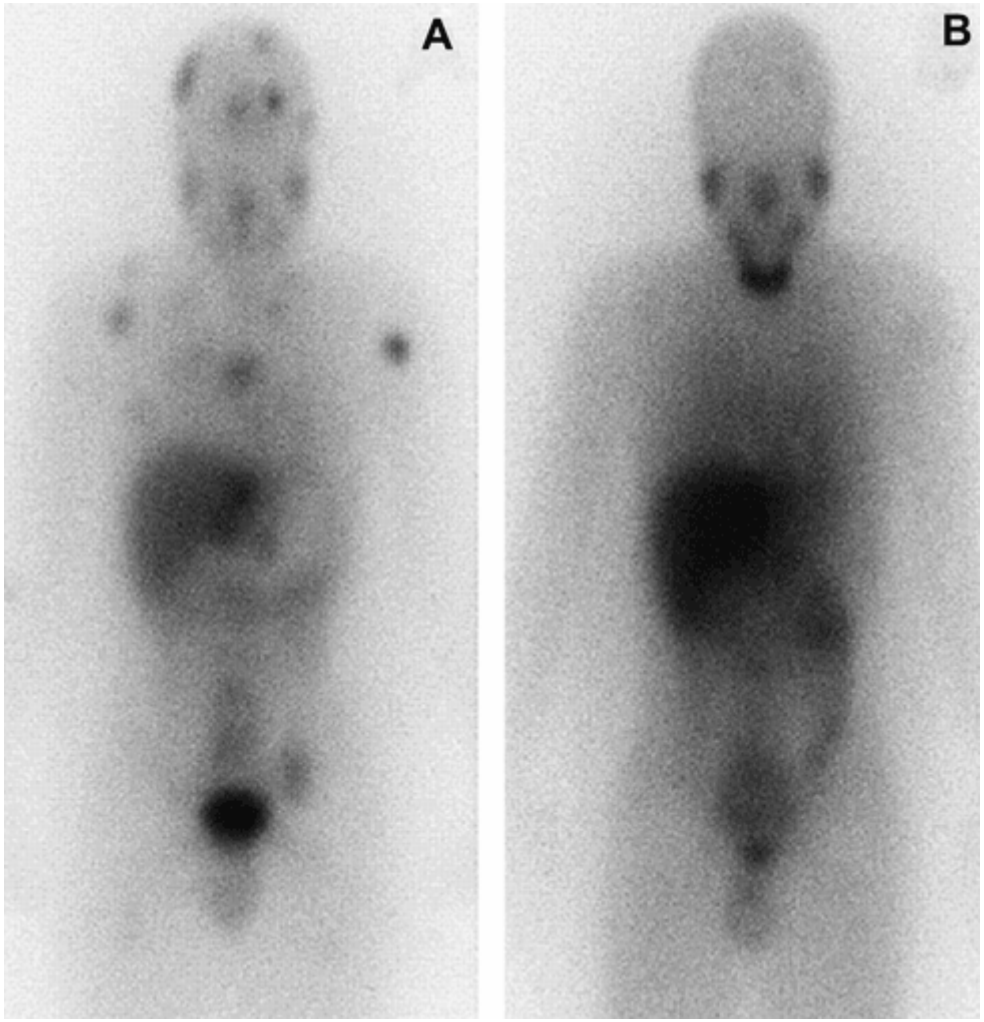

vor Therapie **nach 2x MIBG i.v.**

Myeloablation vor Stammzell-Tx bei AML

Radioimmuntherapie

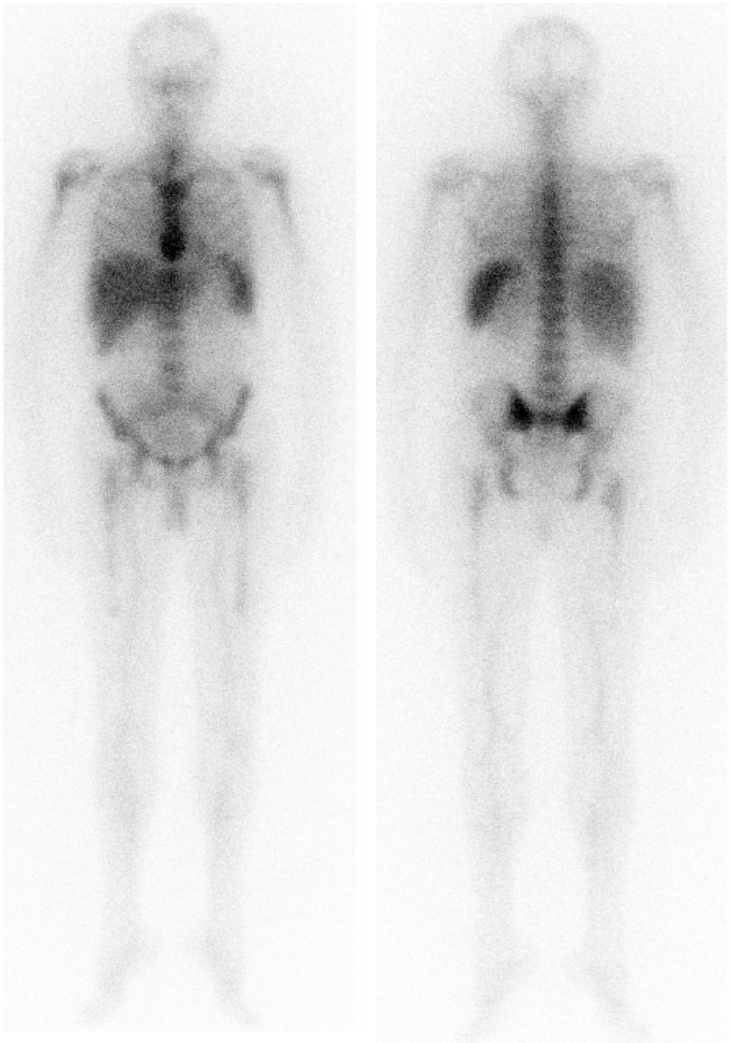

Ganzkörperbestrahlung (12-15 Gy) **mit ^{188}Re-CD66-AK**

Zevalintherapie bei B-Zell Lymphom

Radioimmuntherapie



Zevalin (90Y-Ibritumomab-Tiuxetan (14,8 MBq/kgKG))

Somatostatin Rezeptor Radiotherapie (SRRT) bei NET

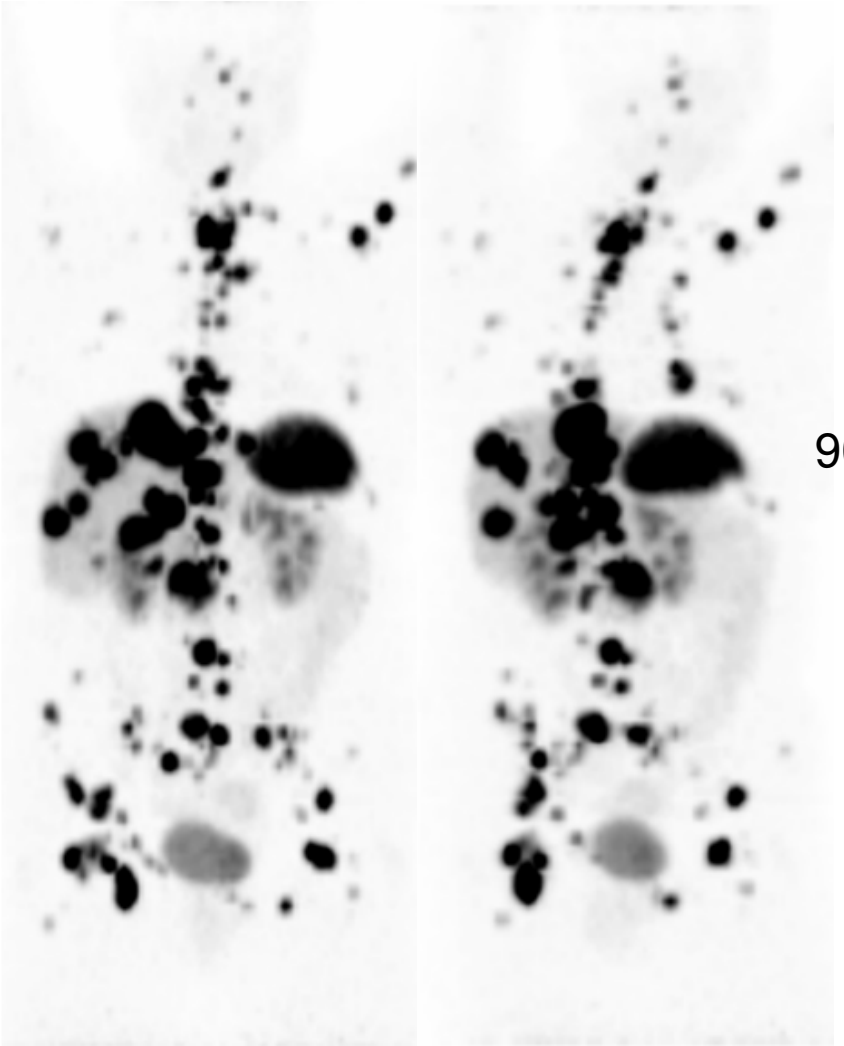

90Y-DOTATOC

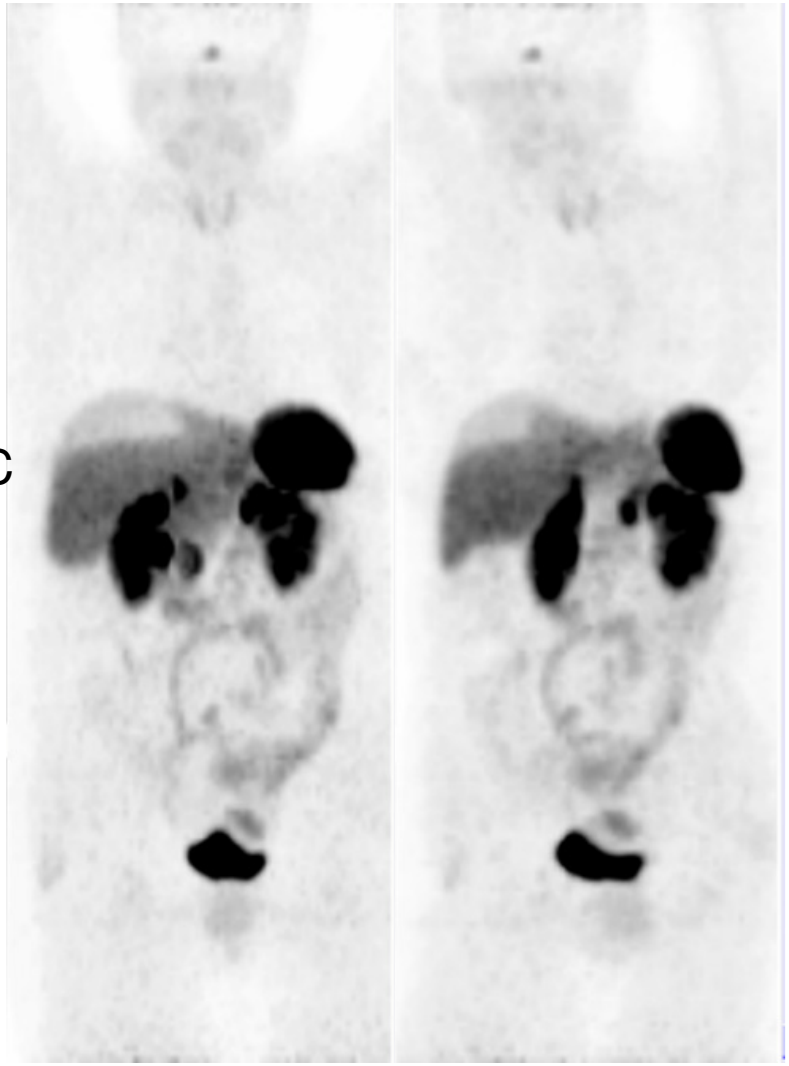

vor Therapie

nach Therapie

Never overload